


9. Východoslovenský bioptický seminár

SD-IAP č. 728

KOŠICE

Jún 2019

Ľ. Straka



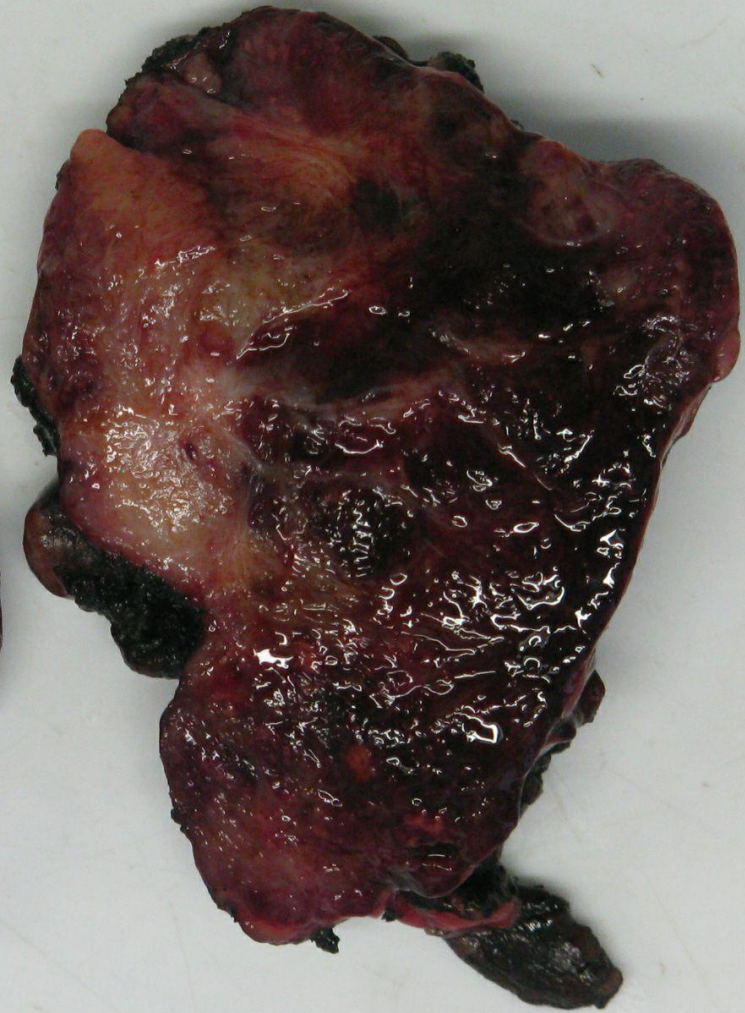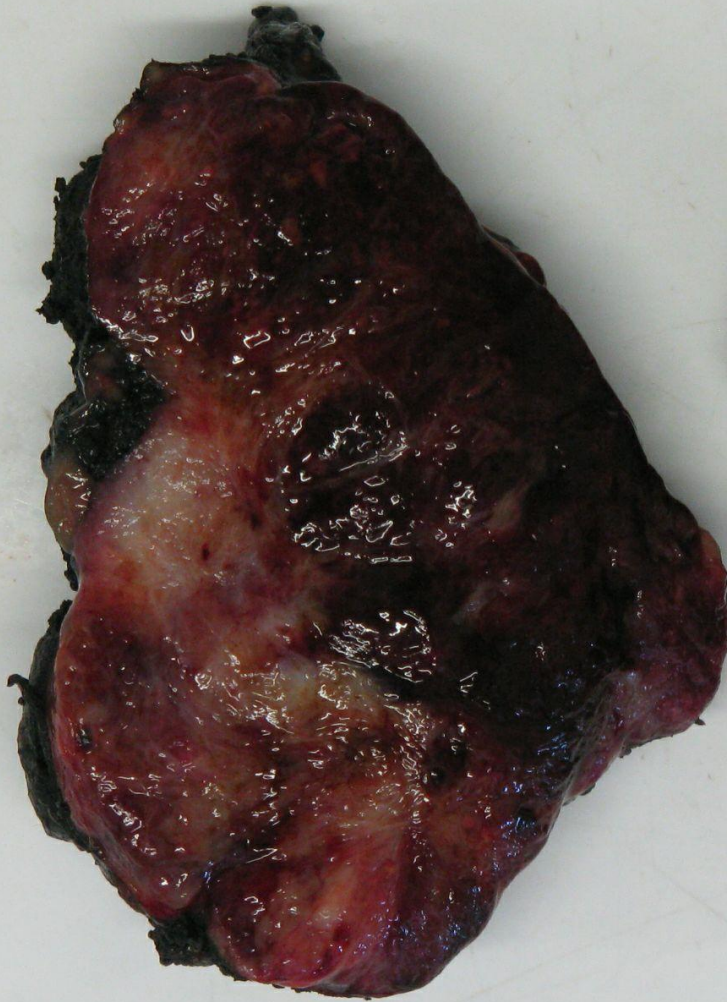
ALPHA MEDICAL



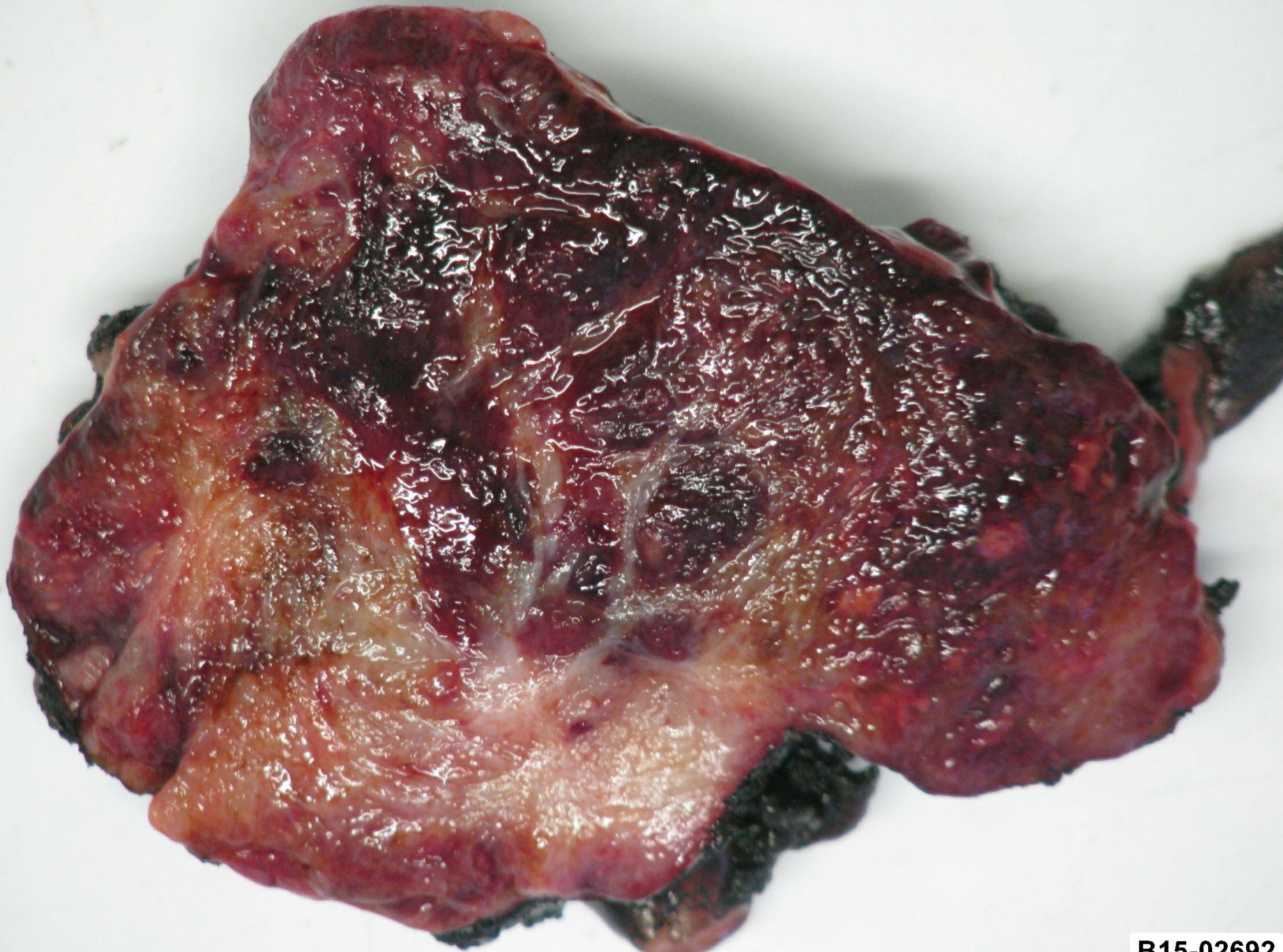
straka.lubomir@alphamedical.sk

SD-IAP č. 728

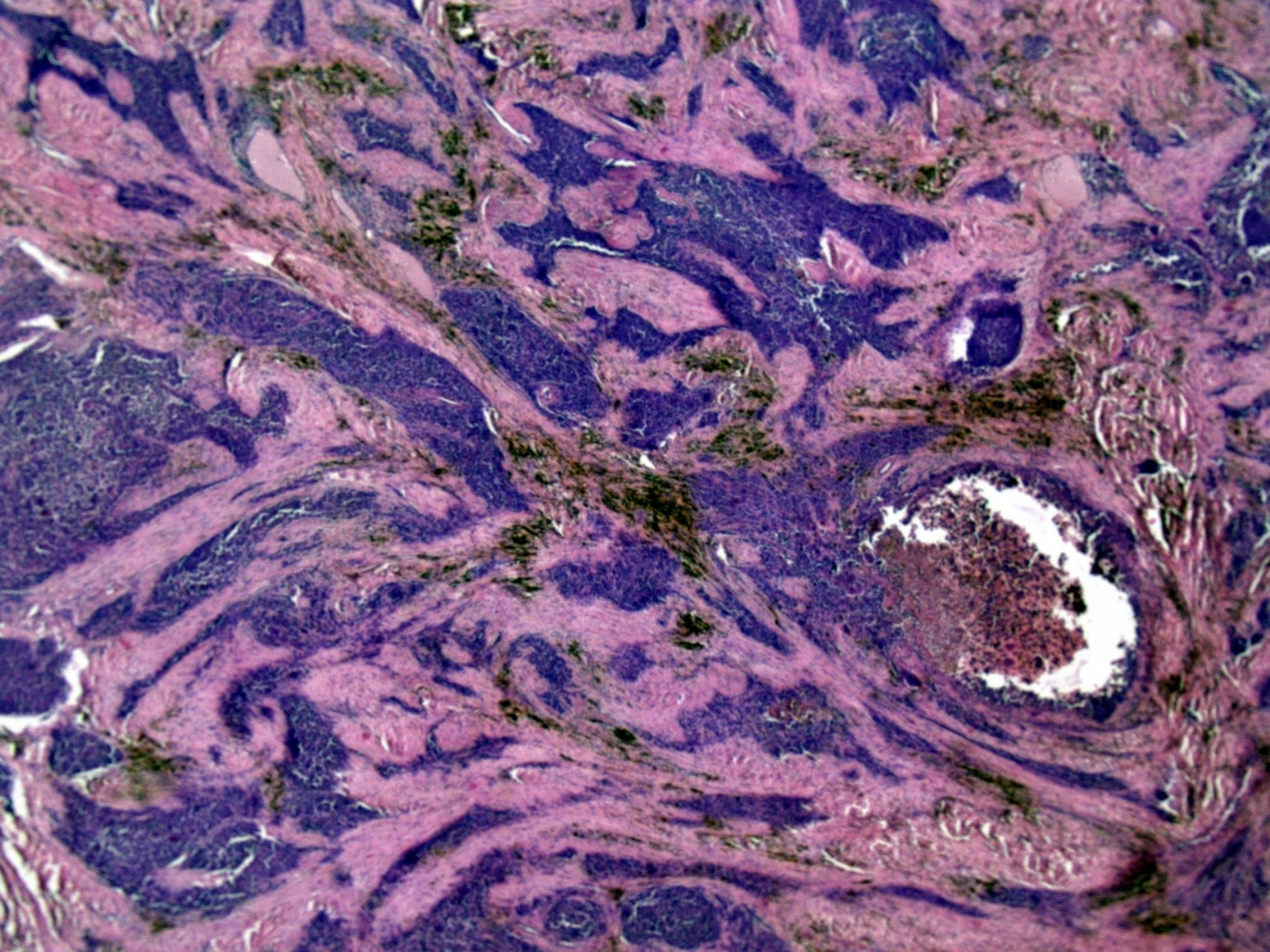
- 48 r. muž
- TU perinea, ľavej oblasti glutea (mimo rekta)
- Lymfadenopatia v inguinách, Th11, LS prechode a retroperitoneu (na CT)
- Excíza veľkosti 75 x 50 x 50 mm

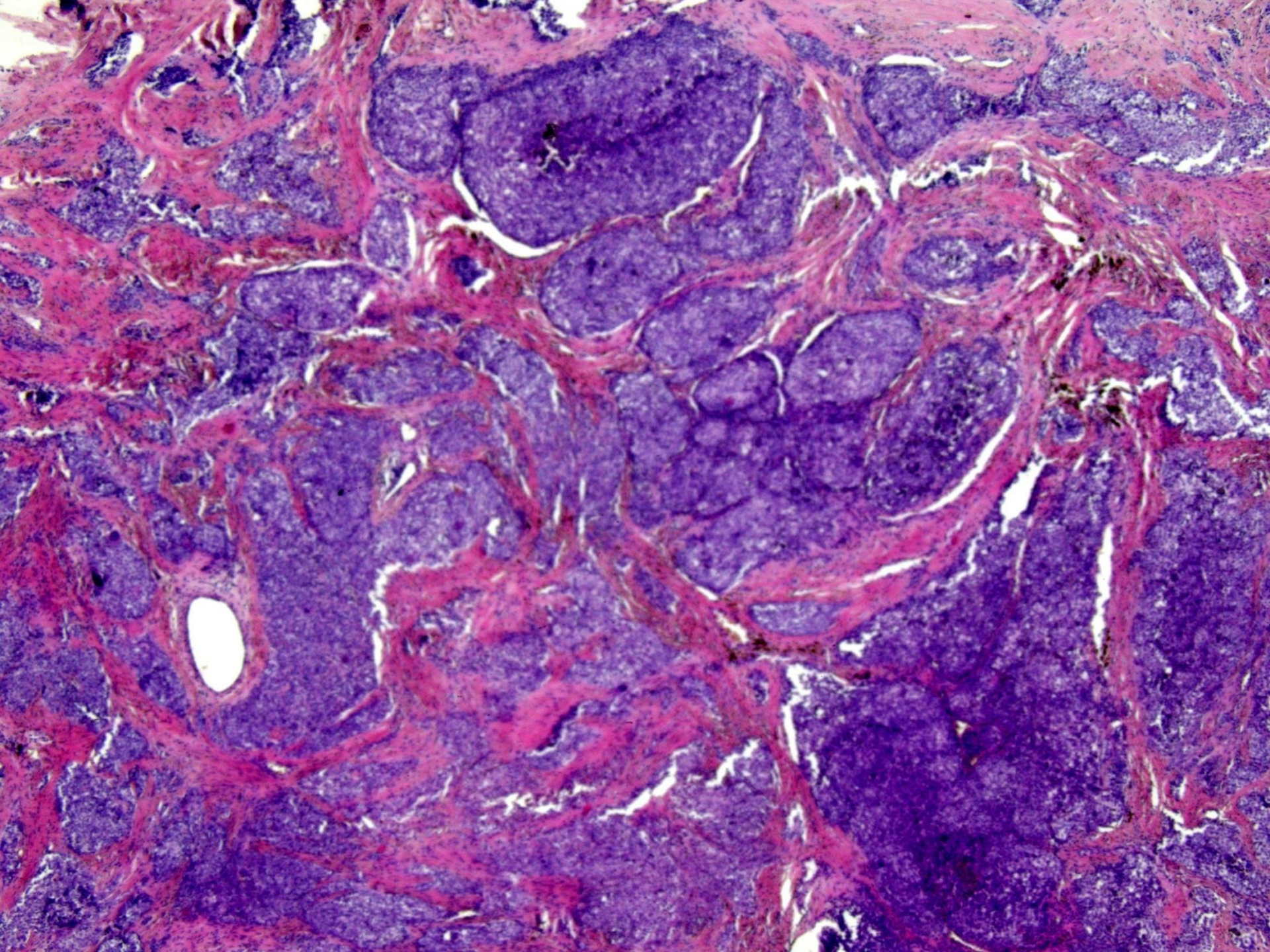


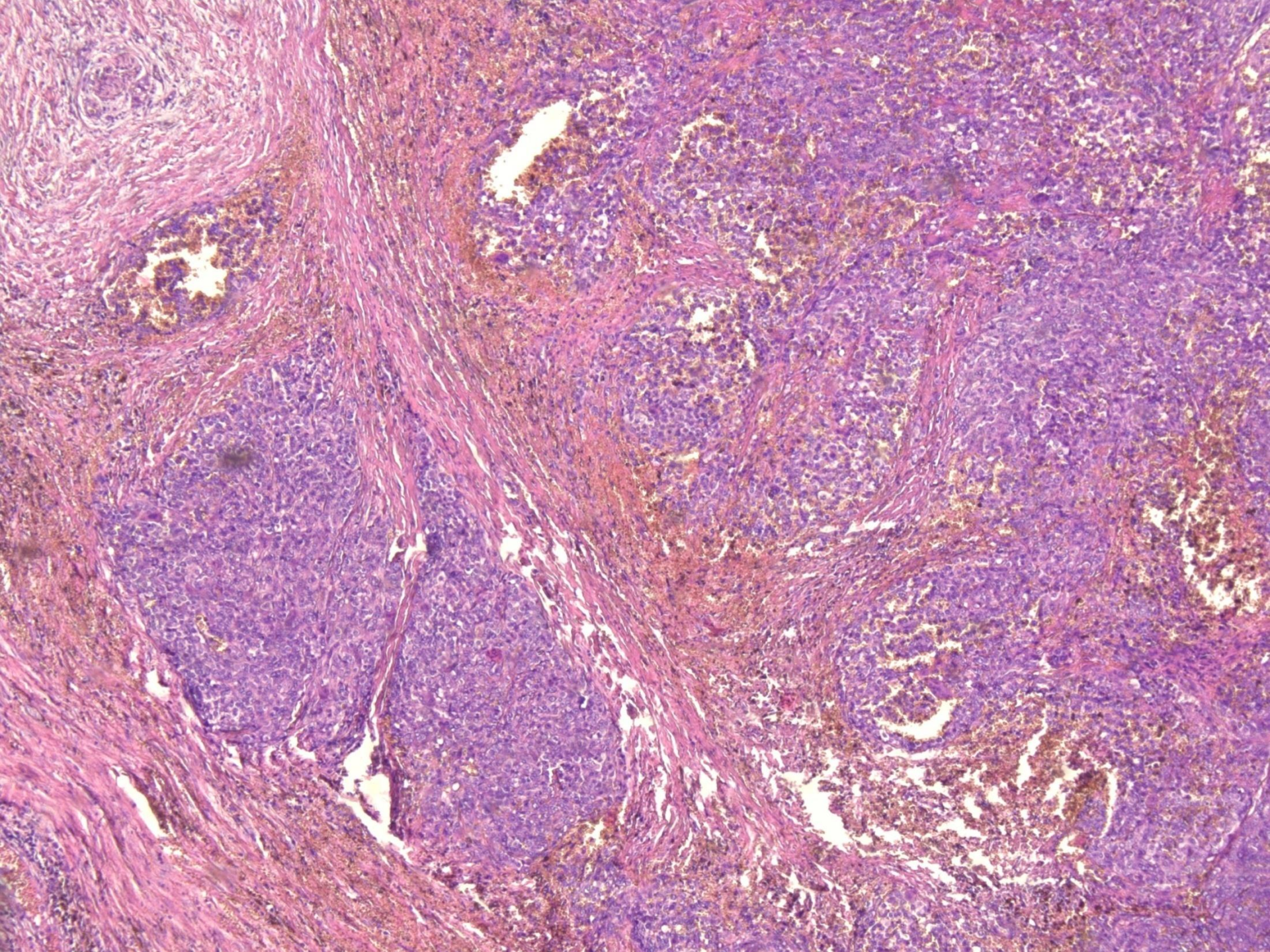
B15-02692

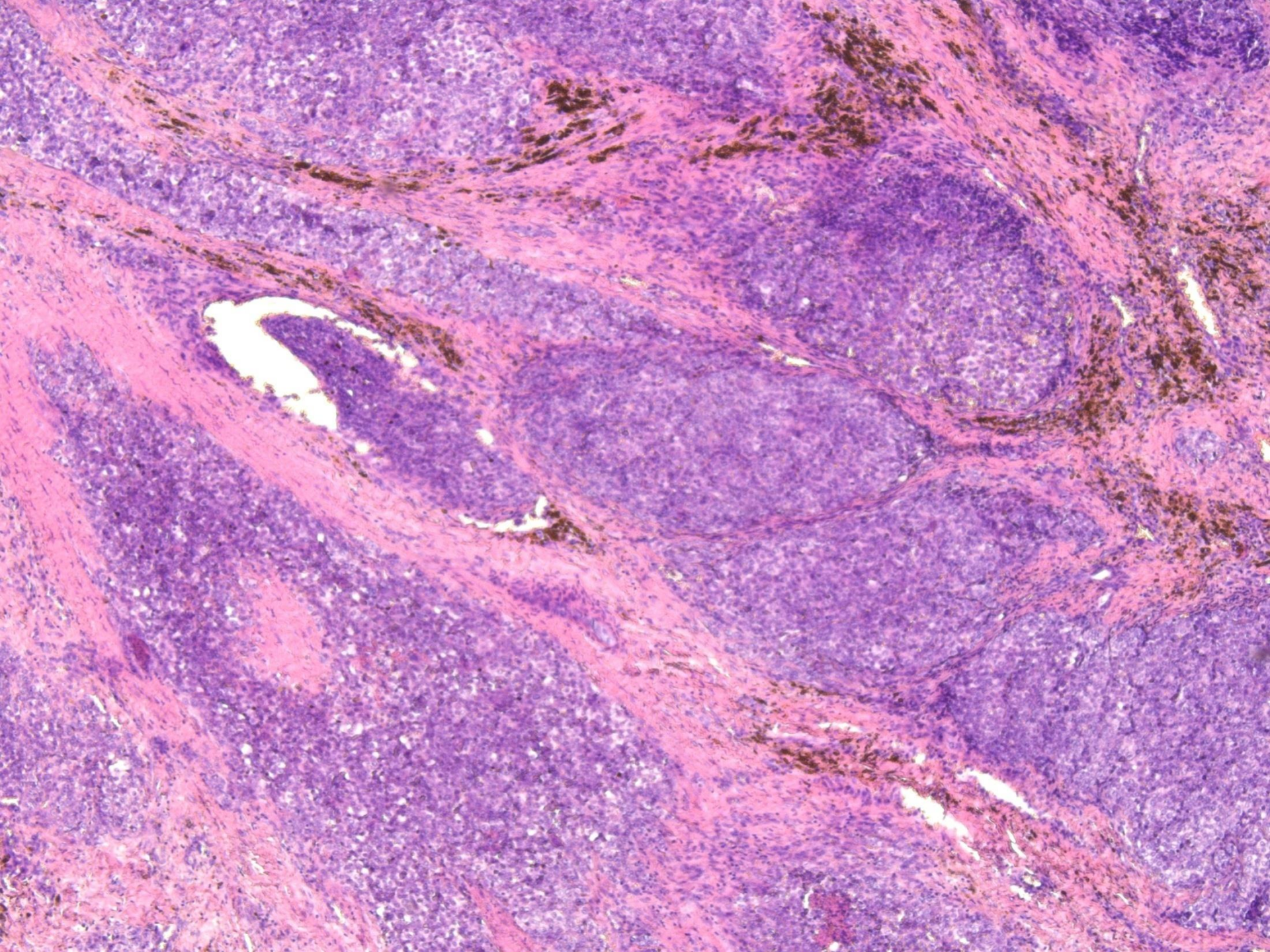


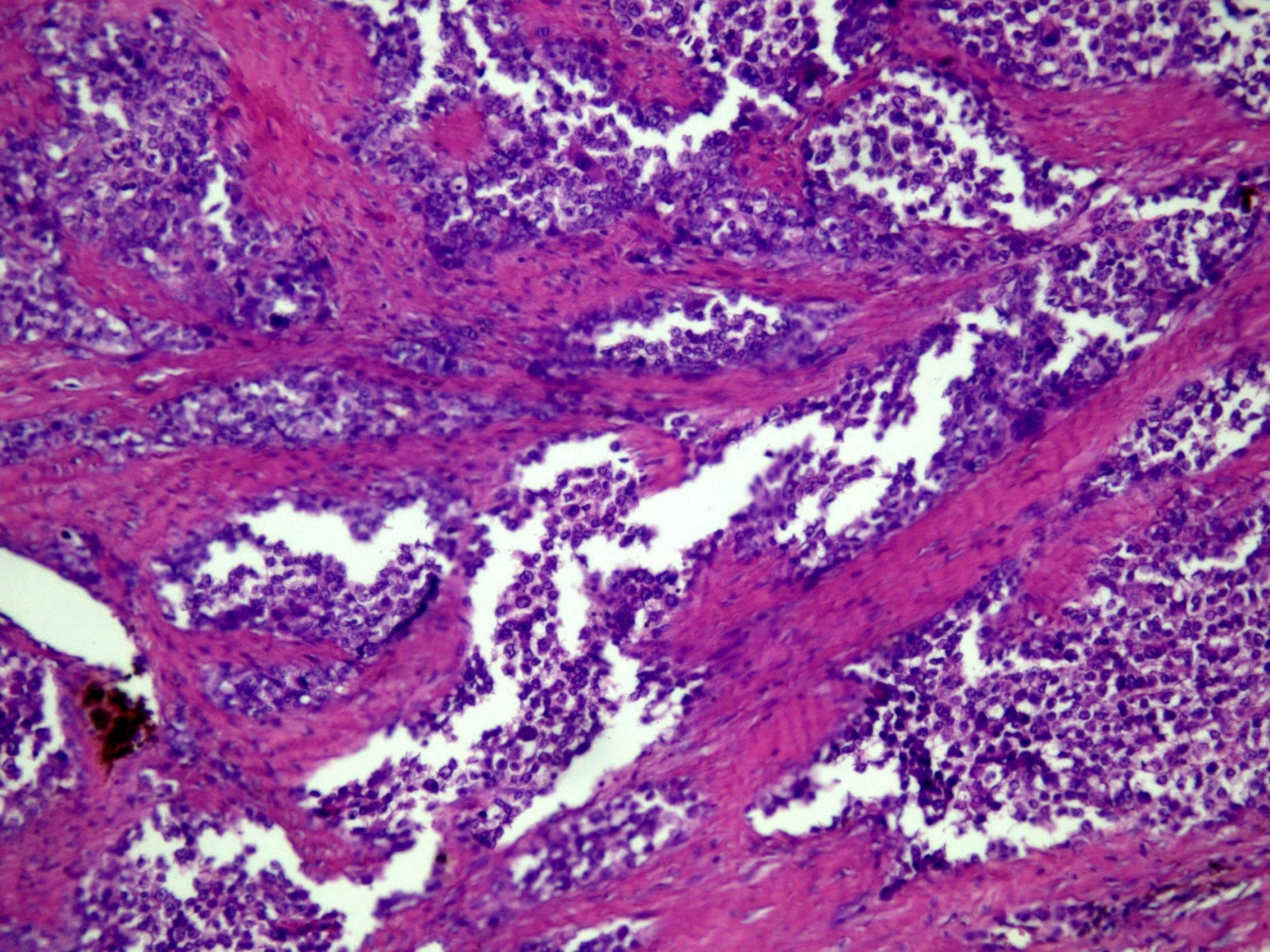
B15-02692

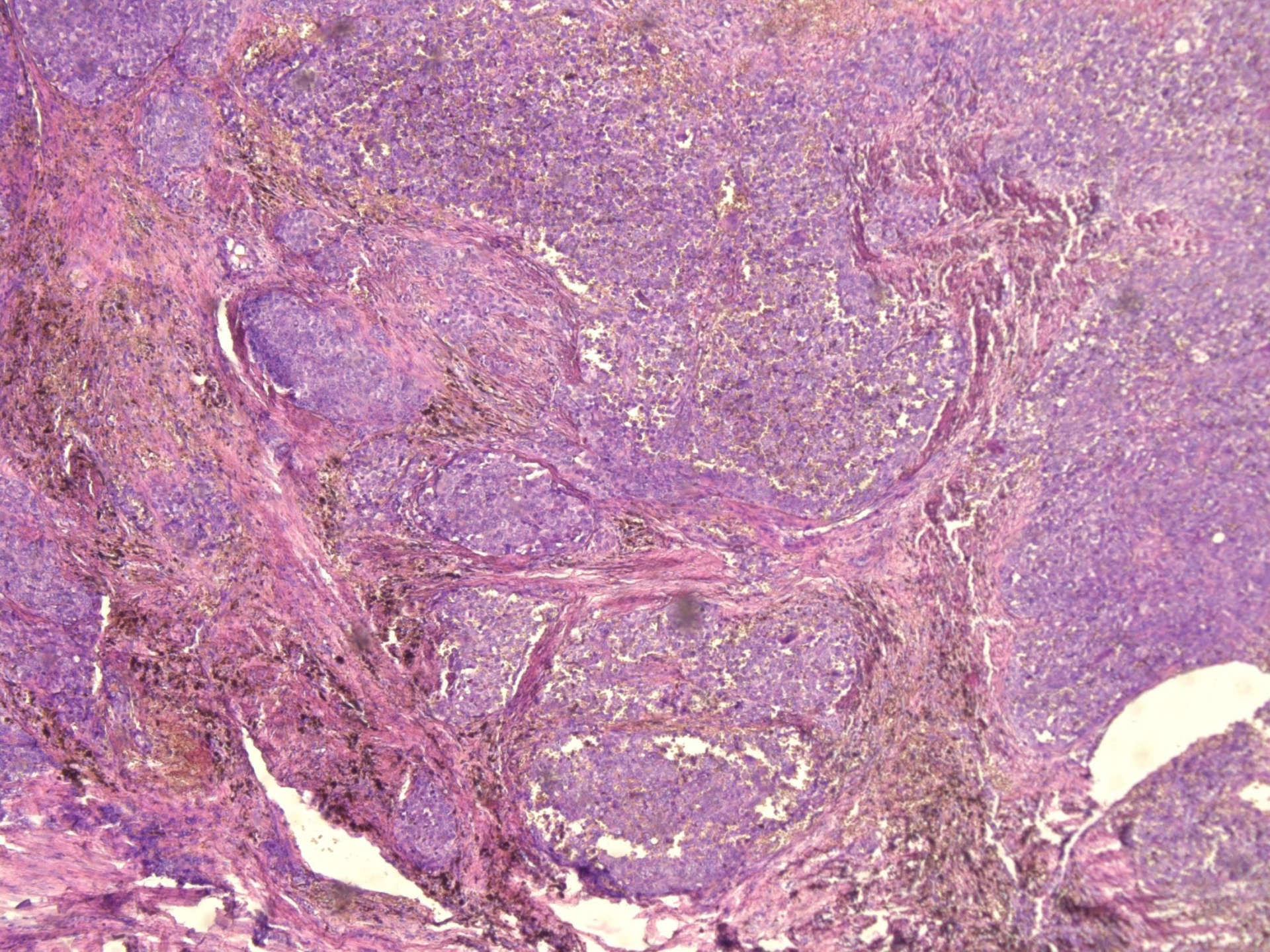


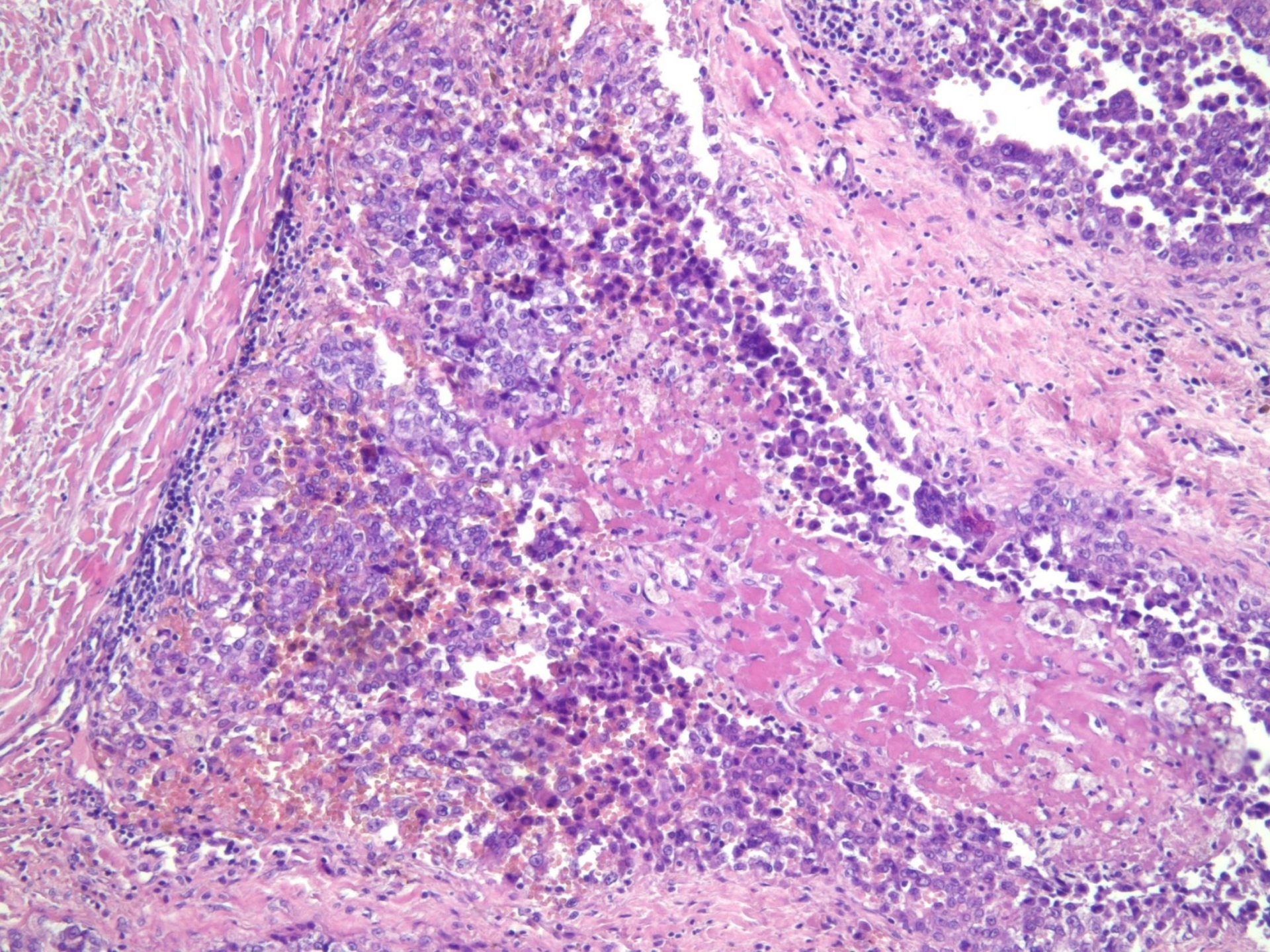


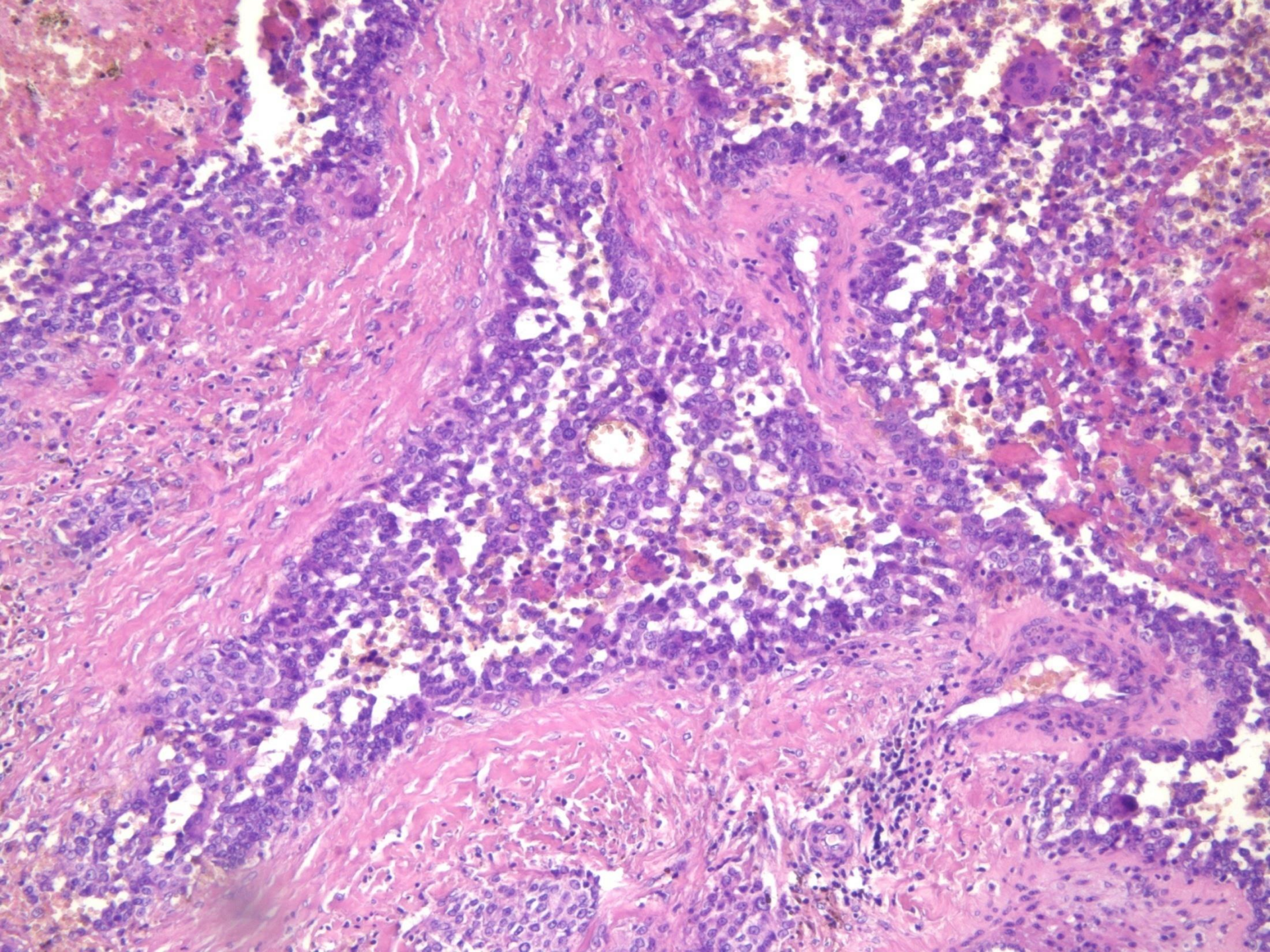


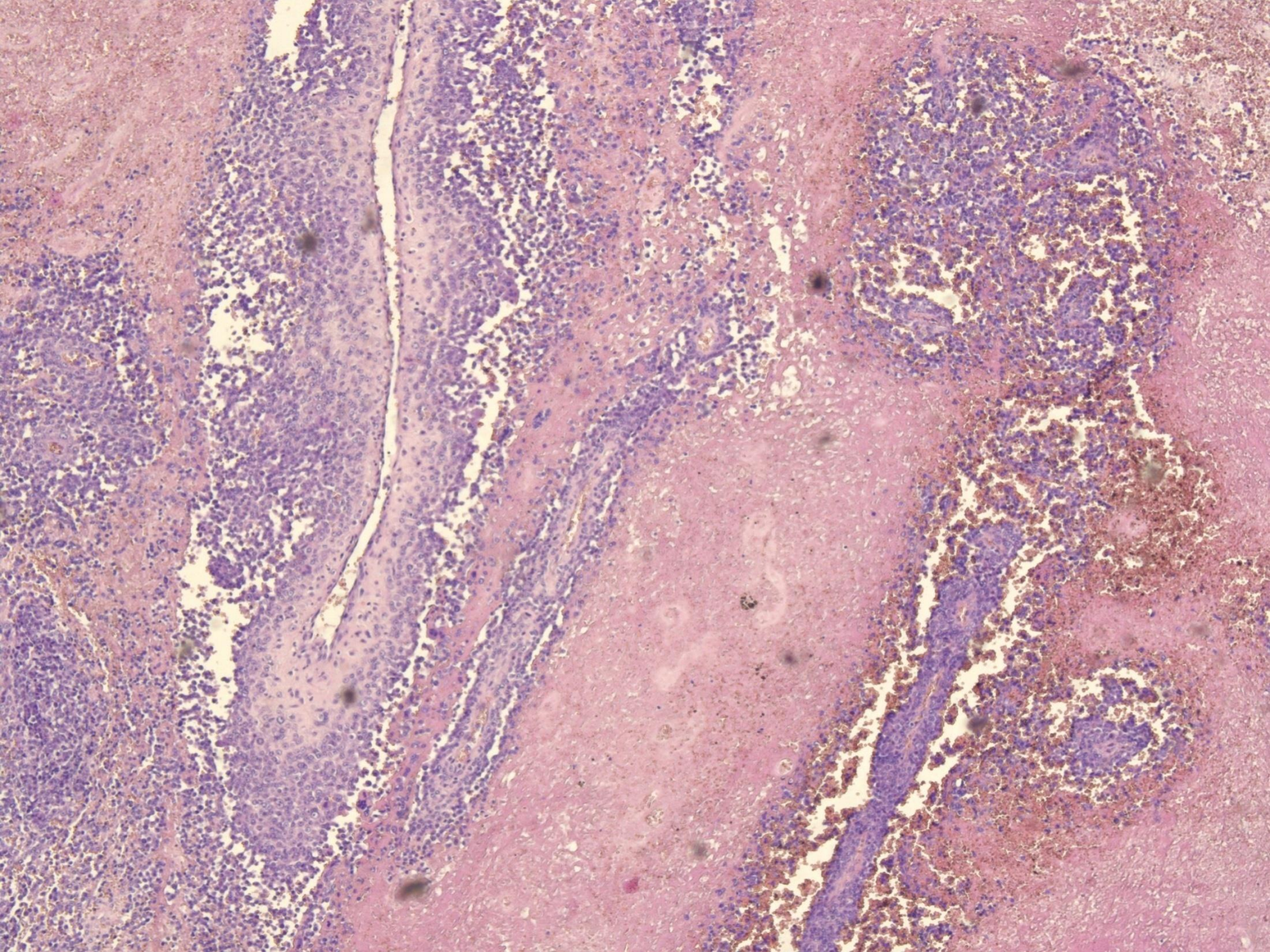


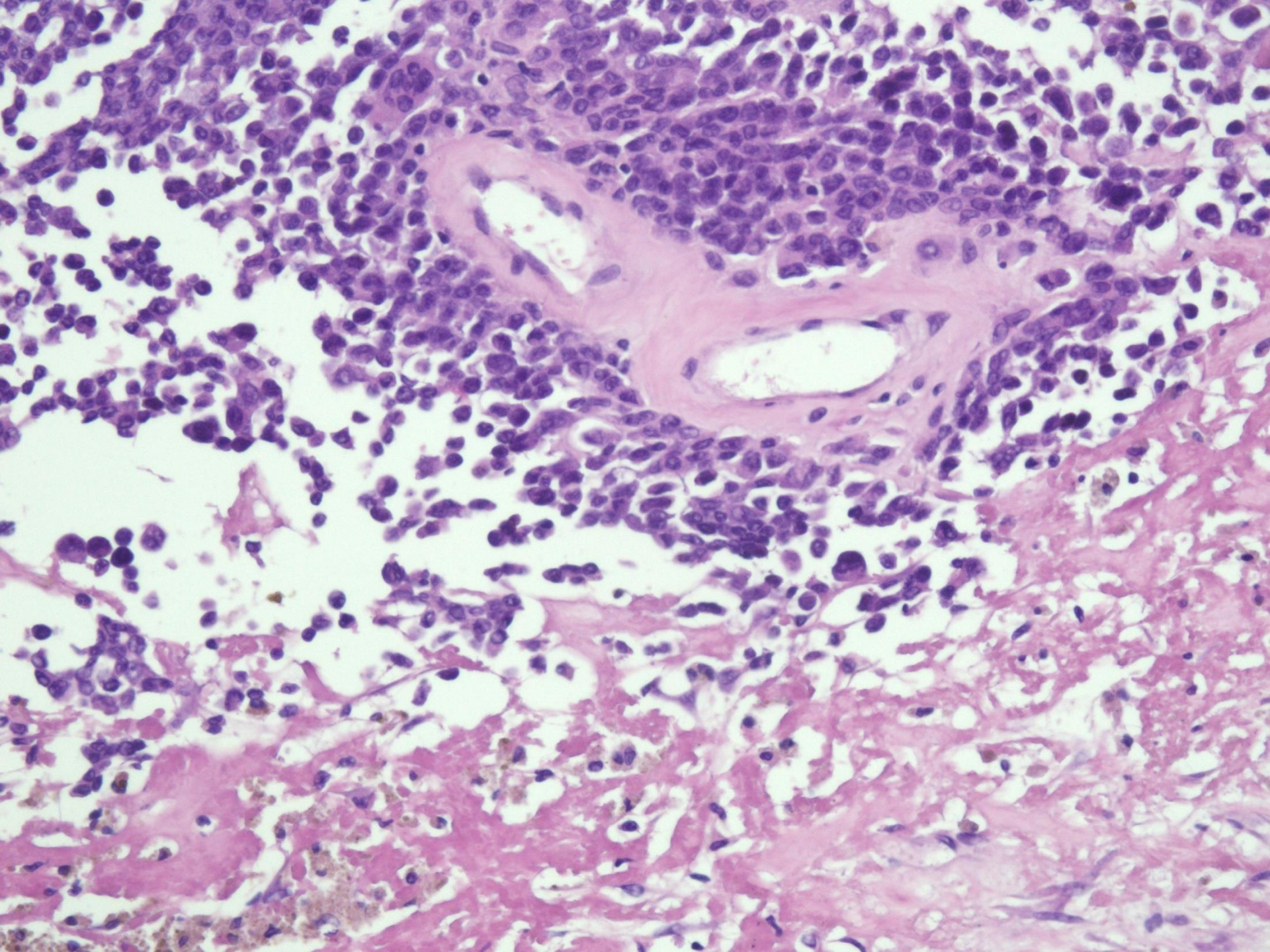


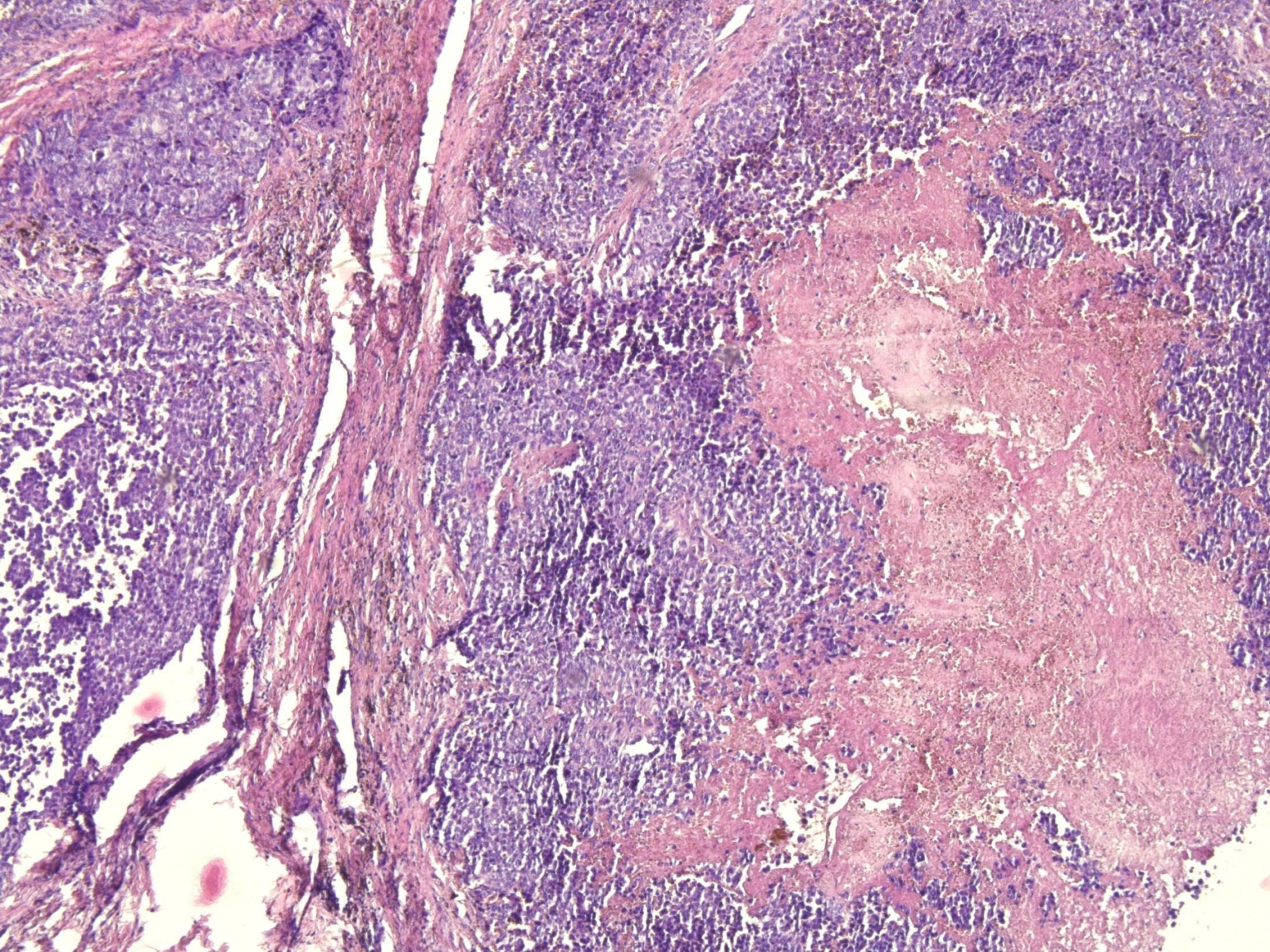


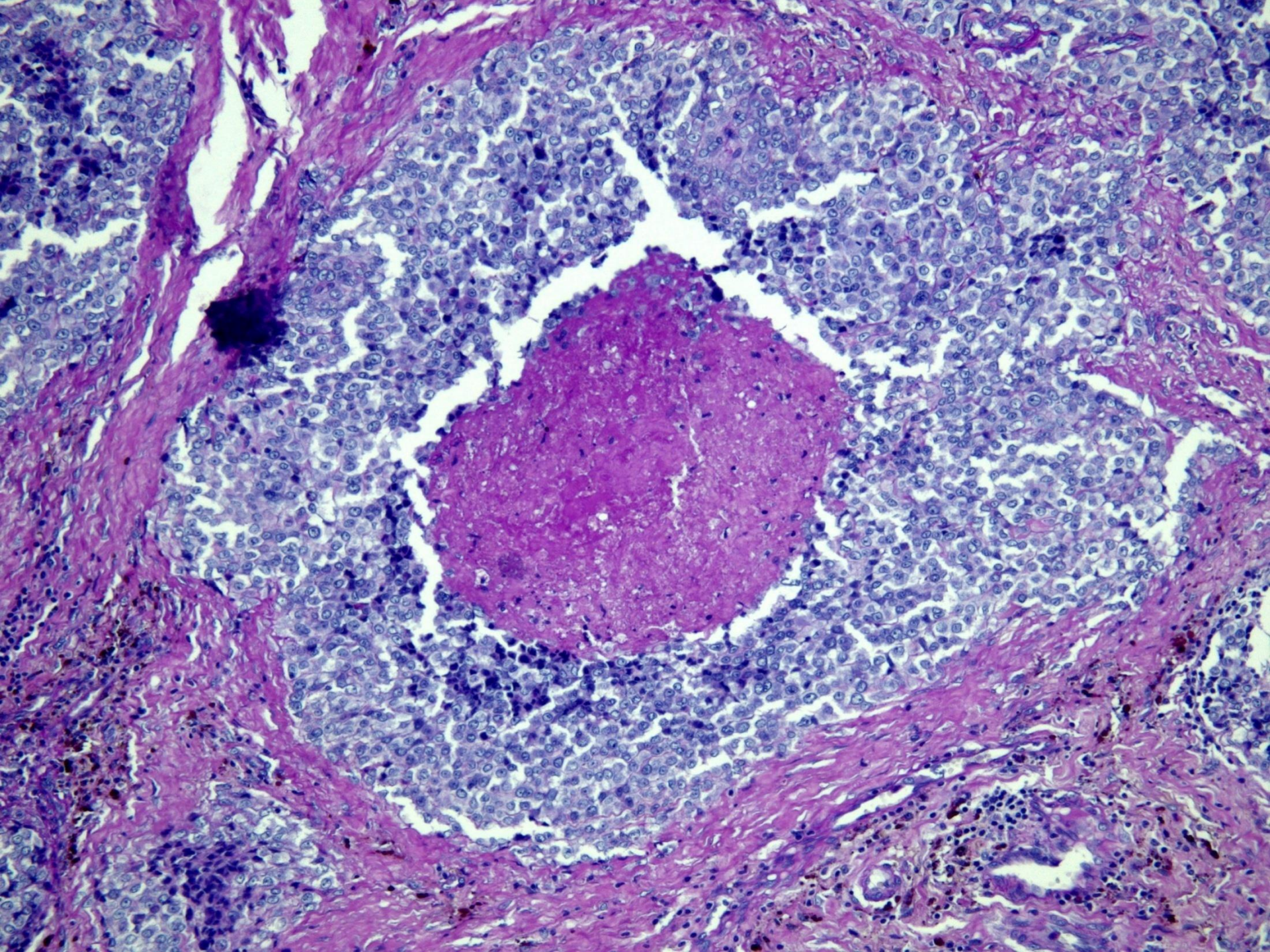


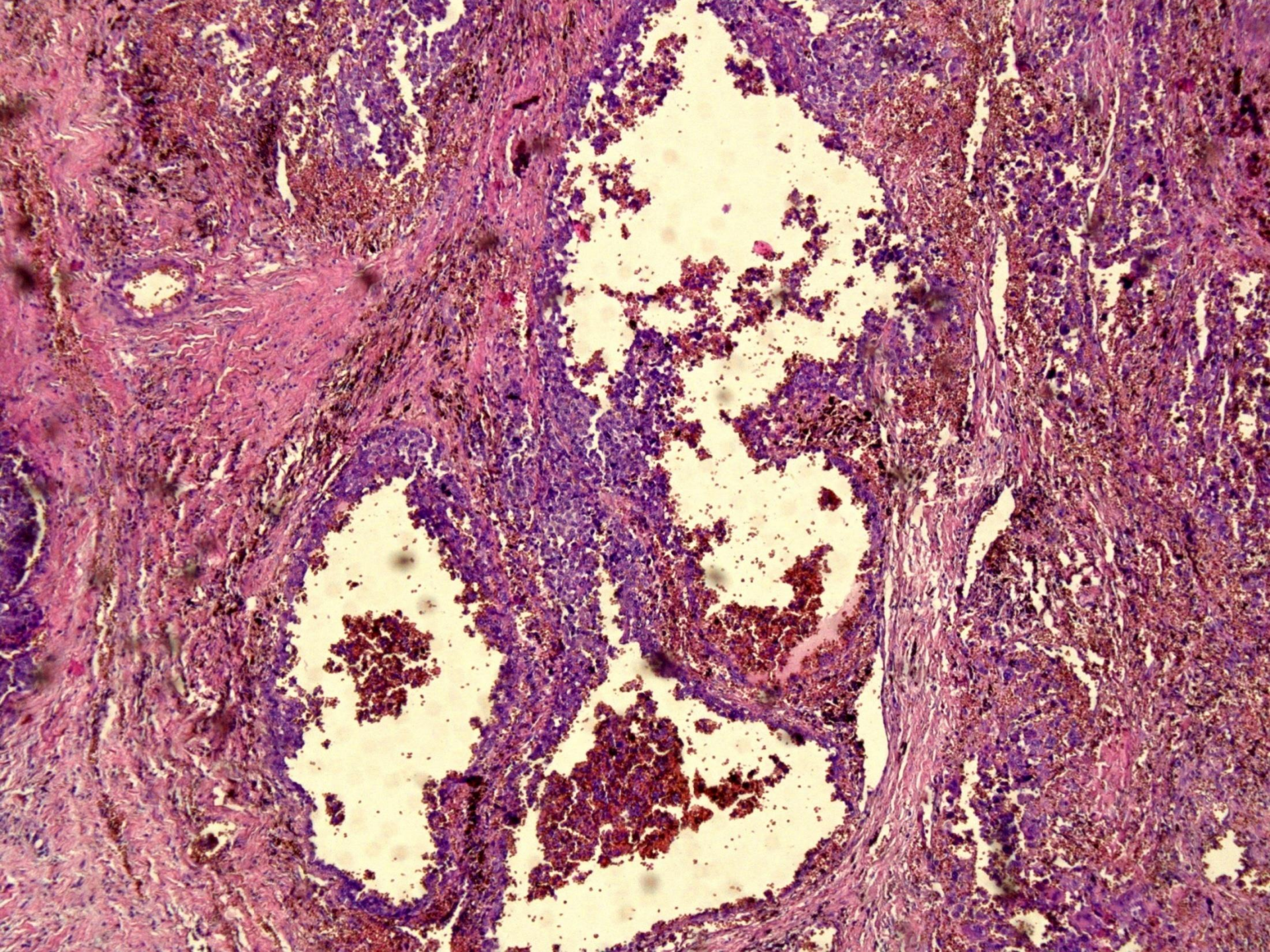


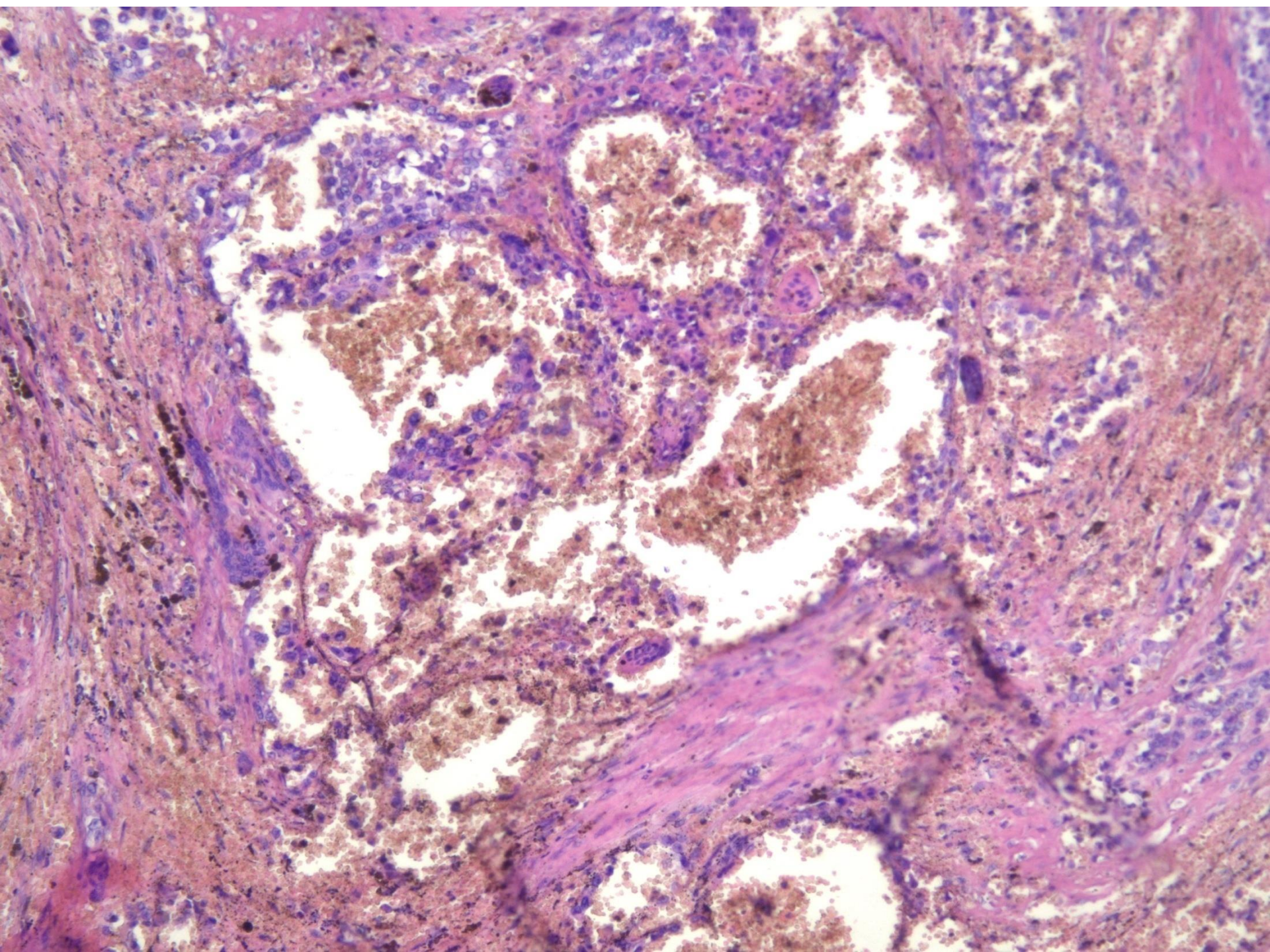


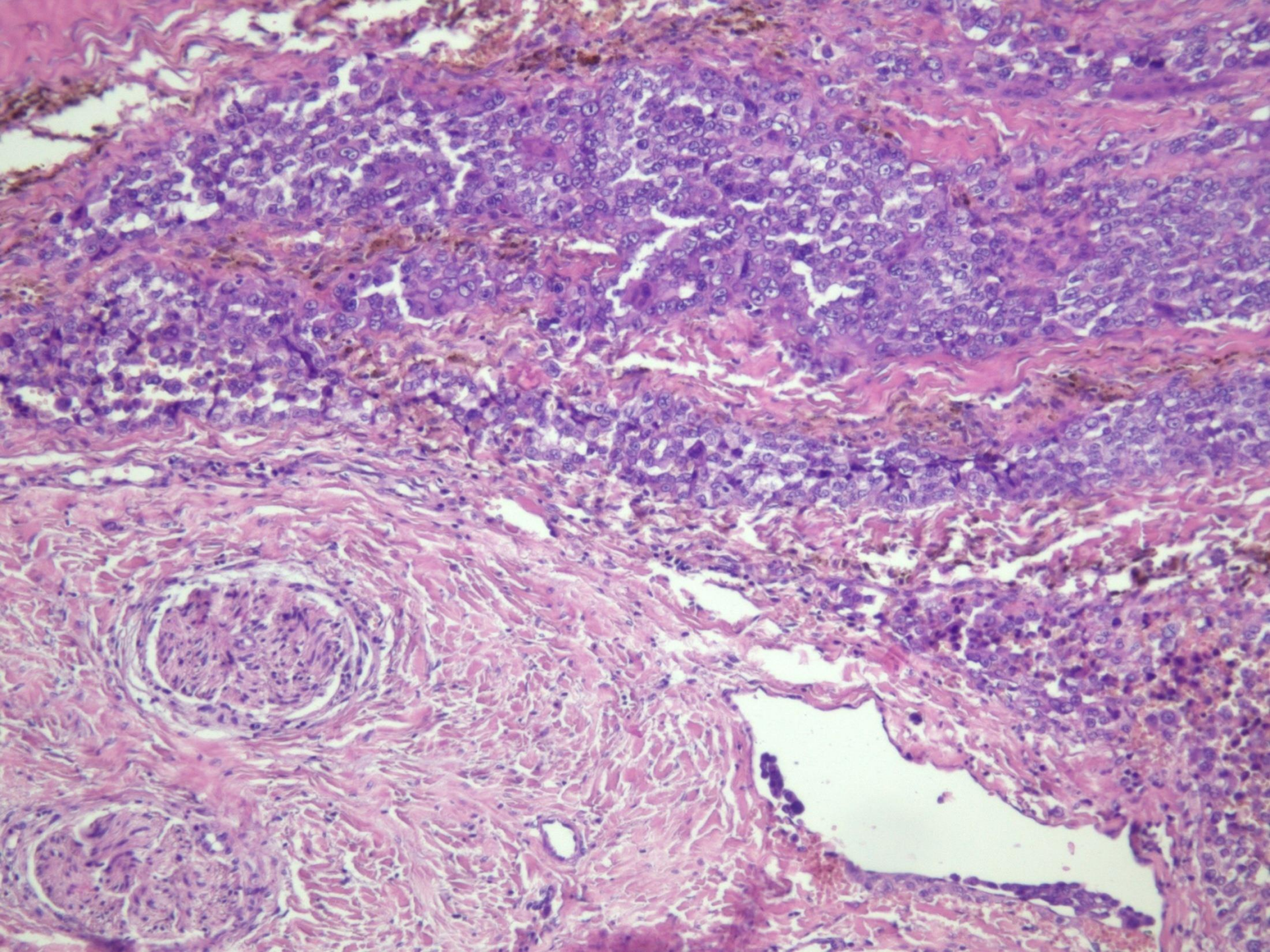


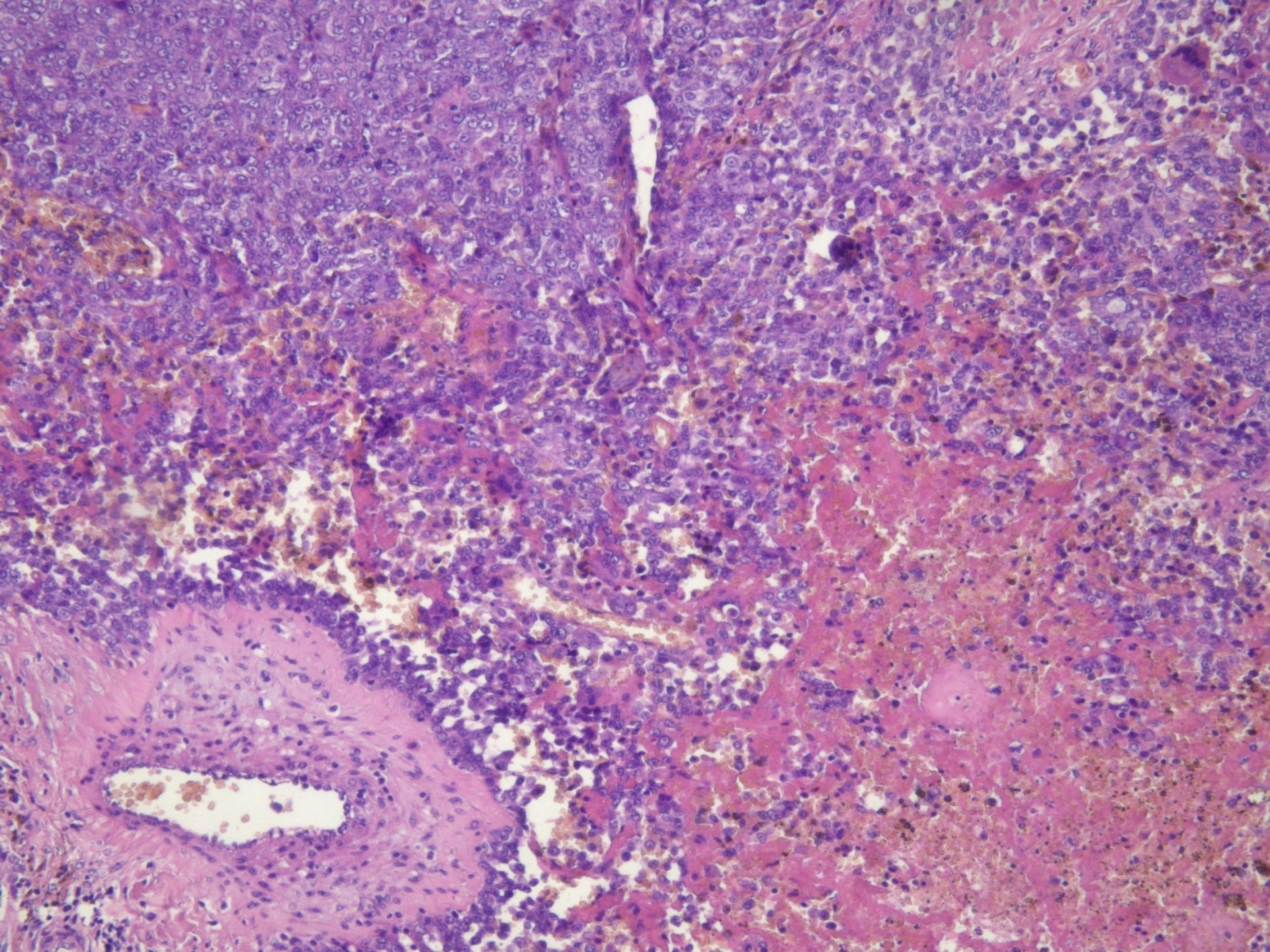


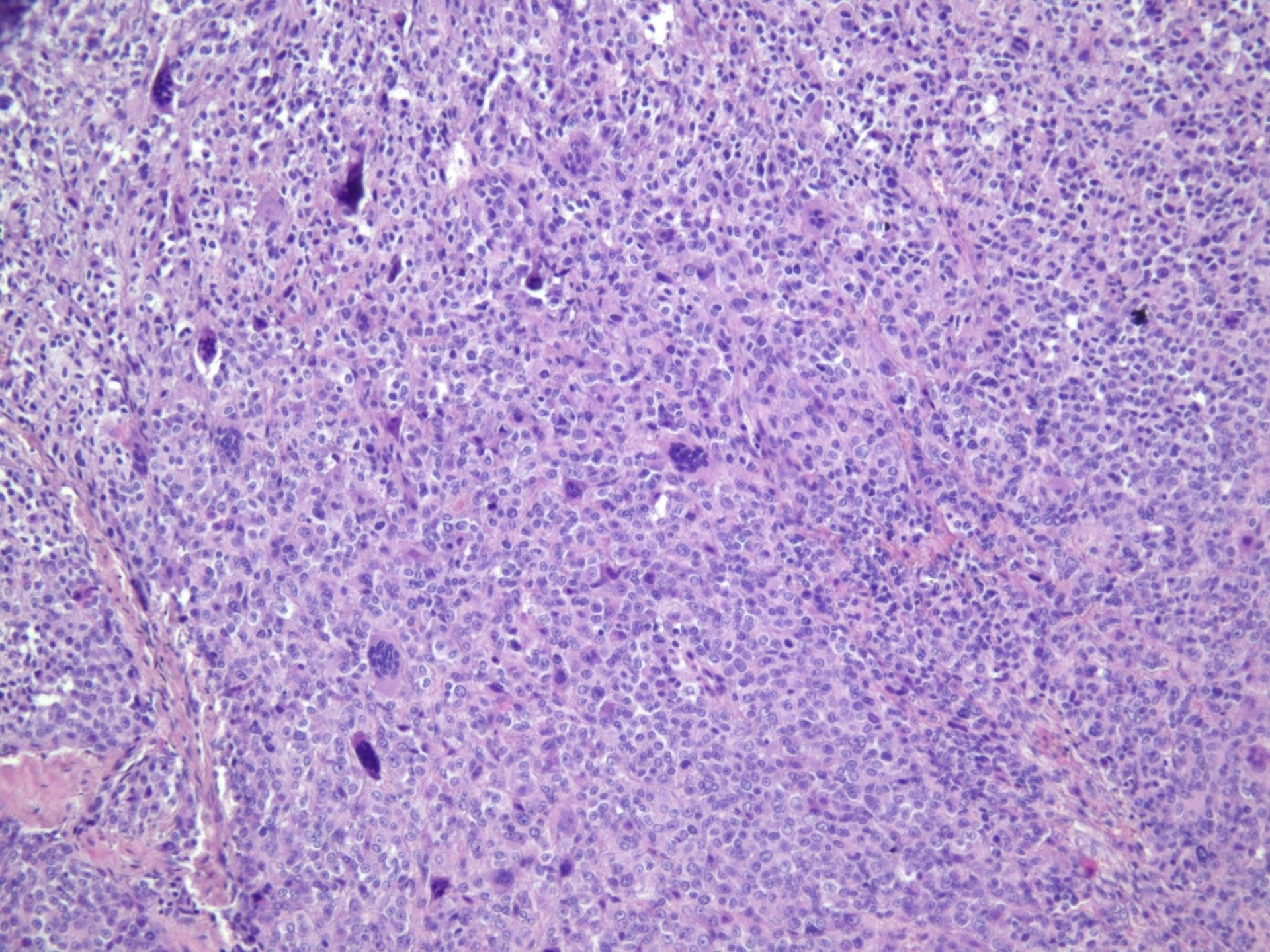


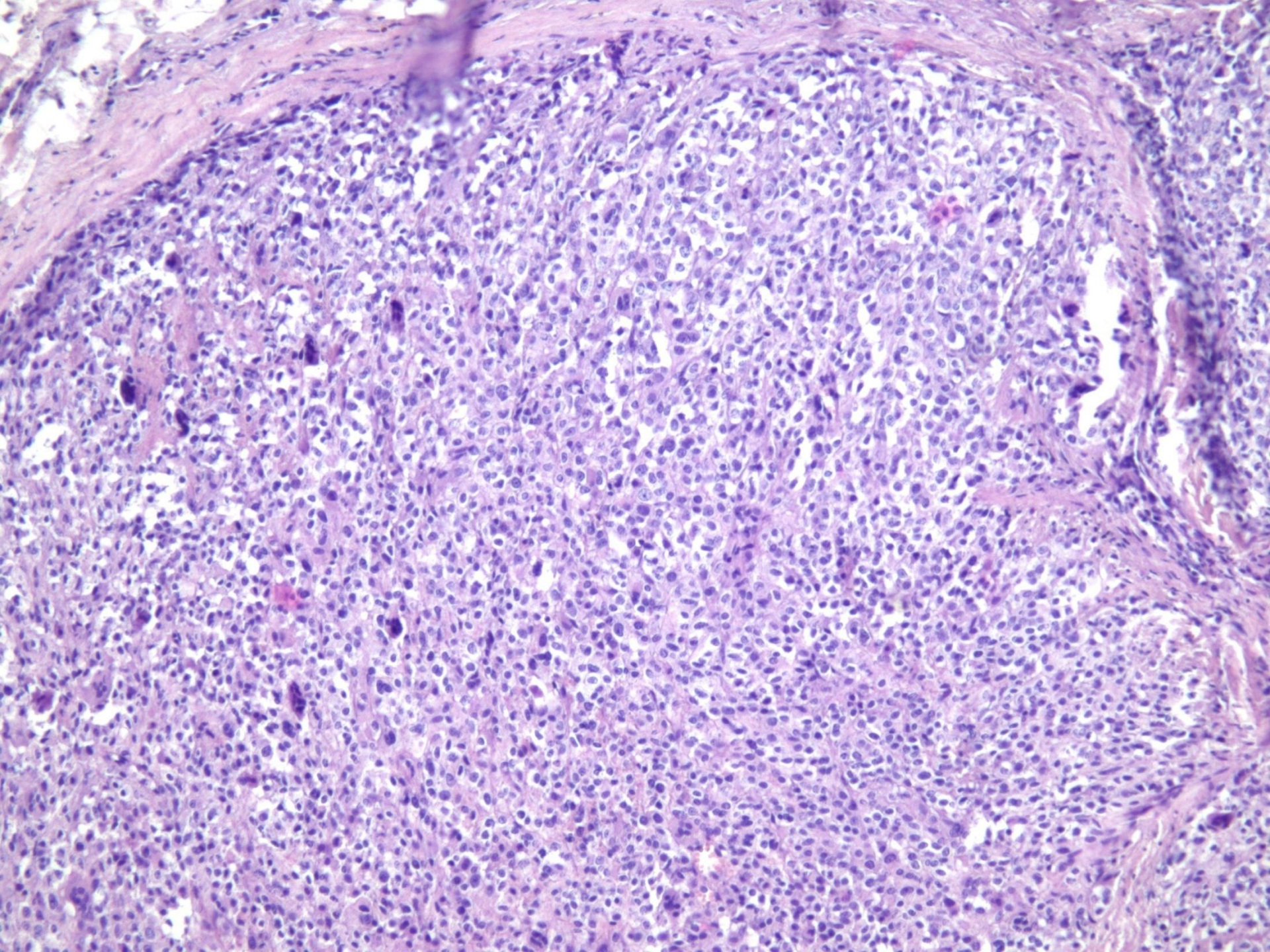


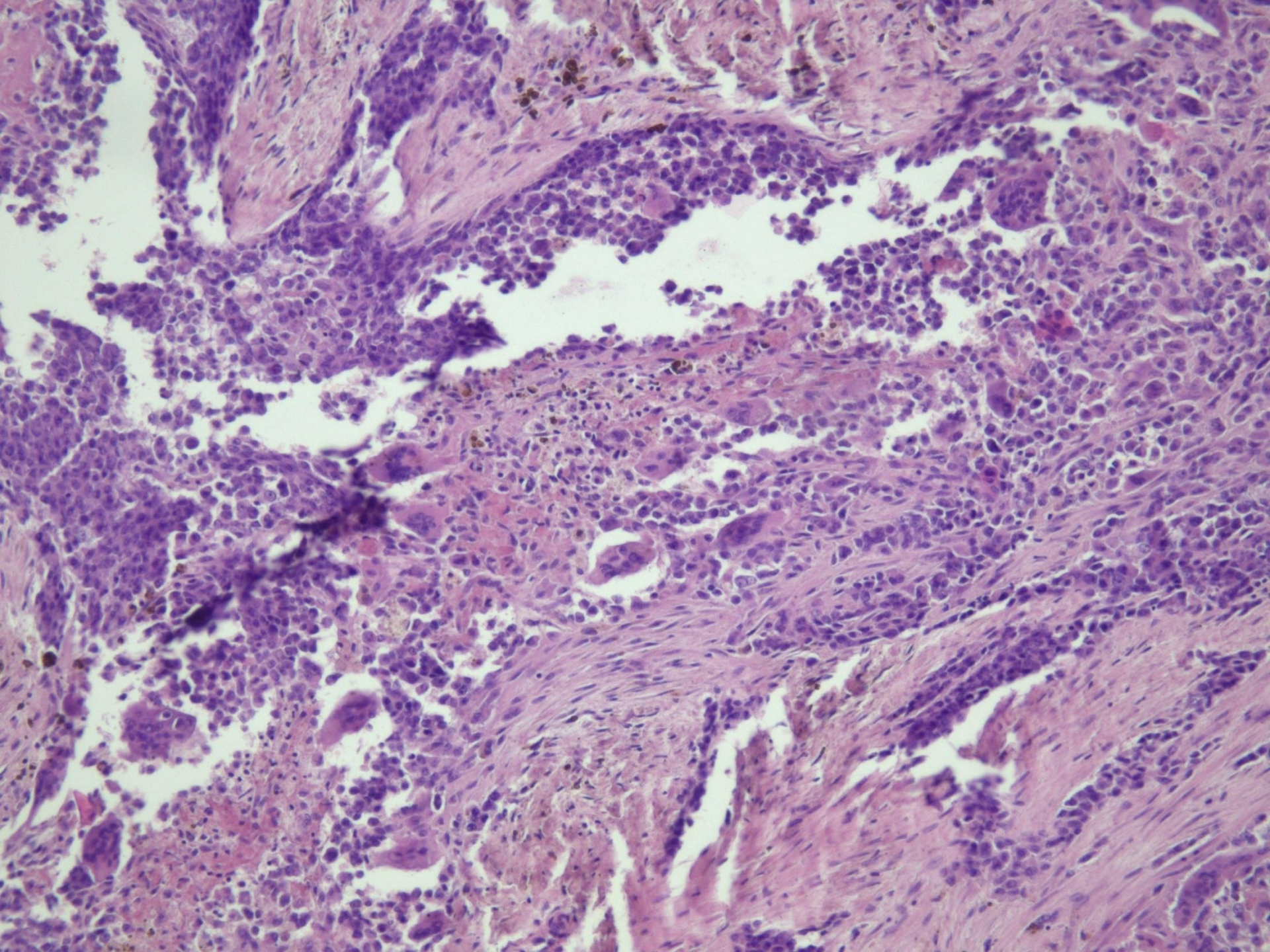


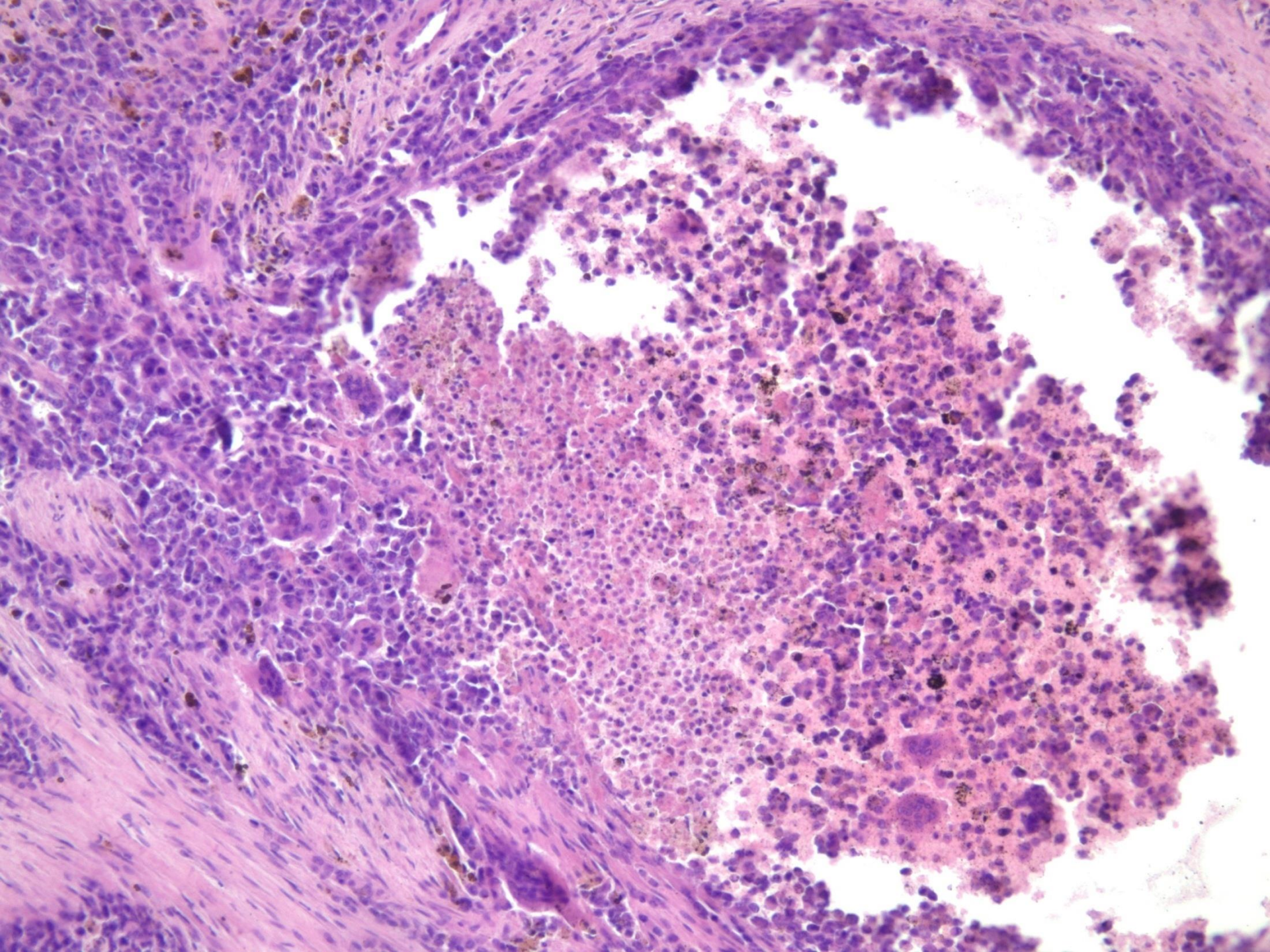


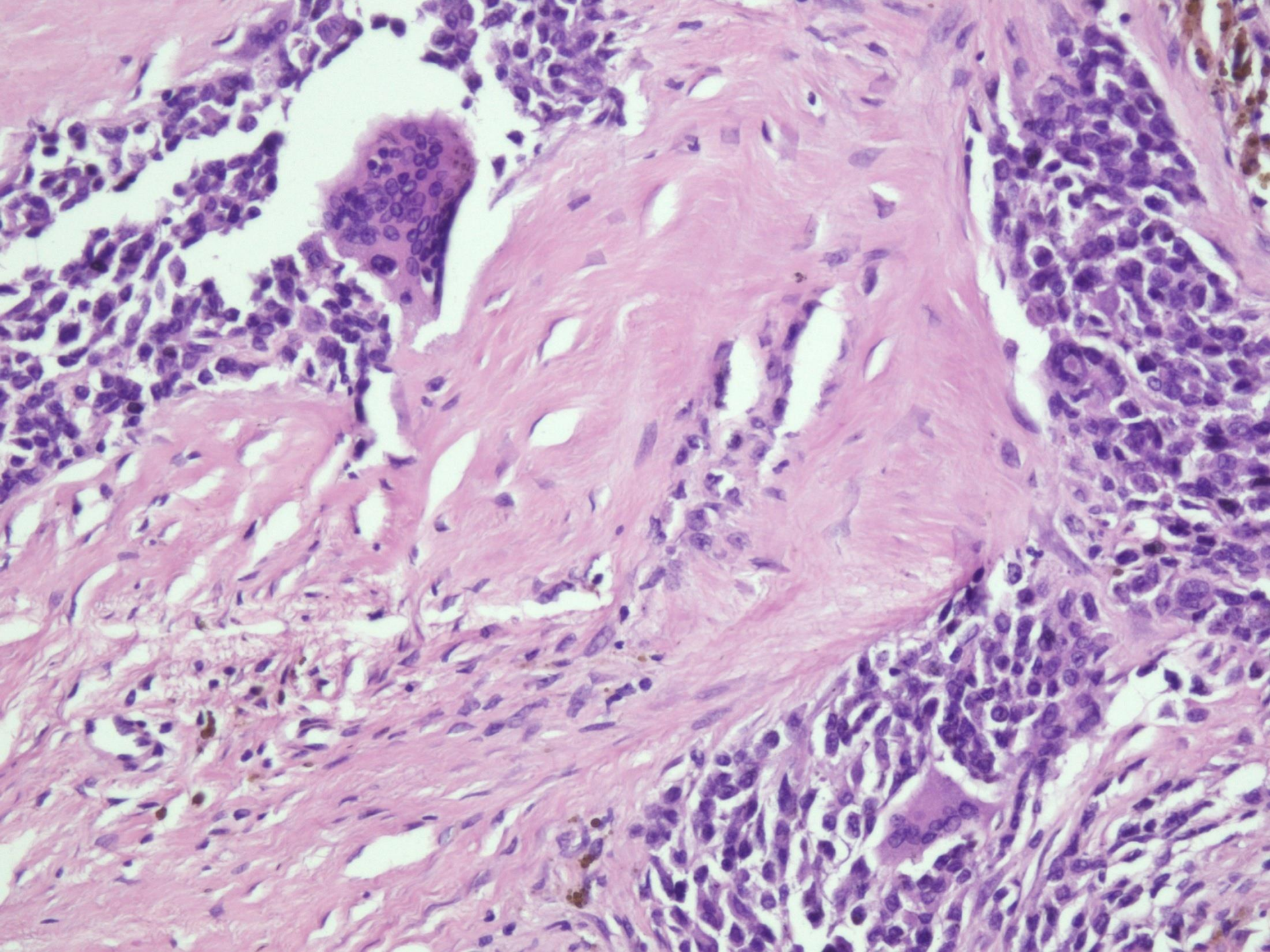


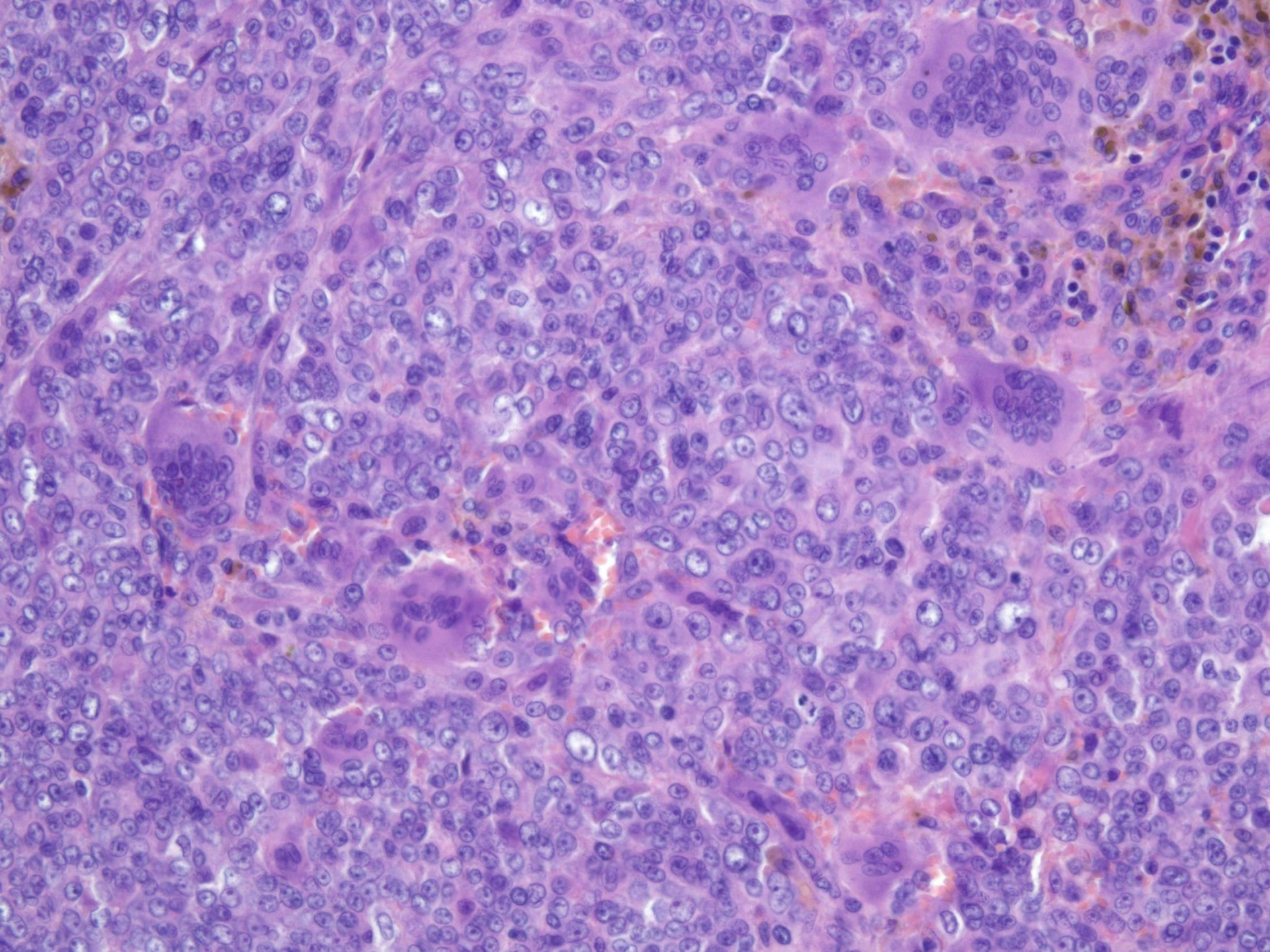


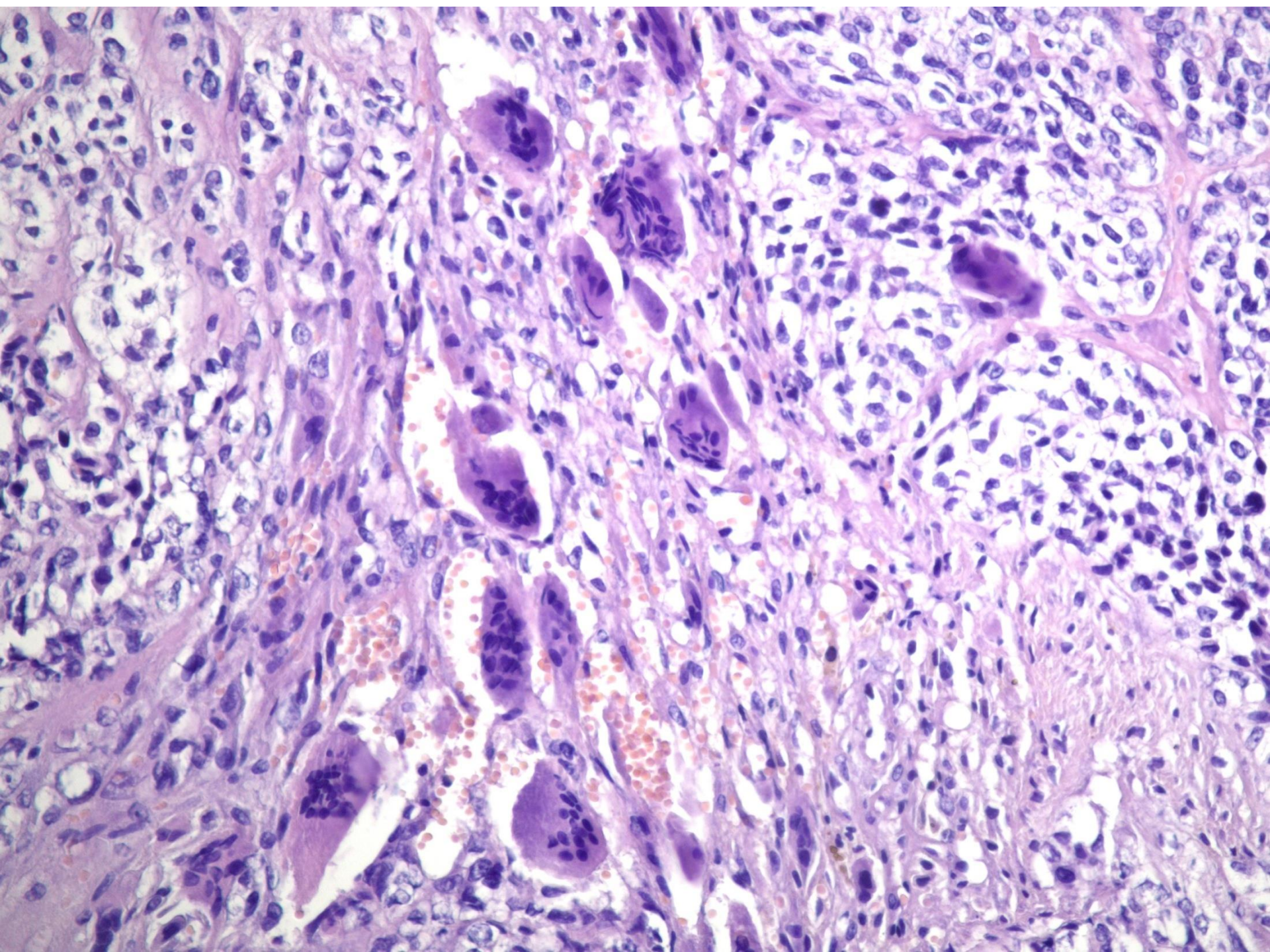


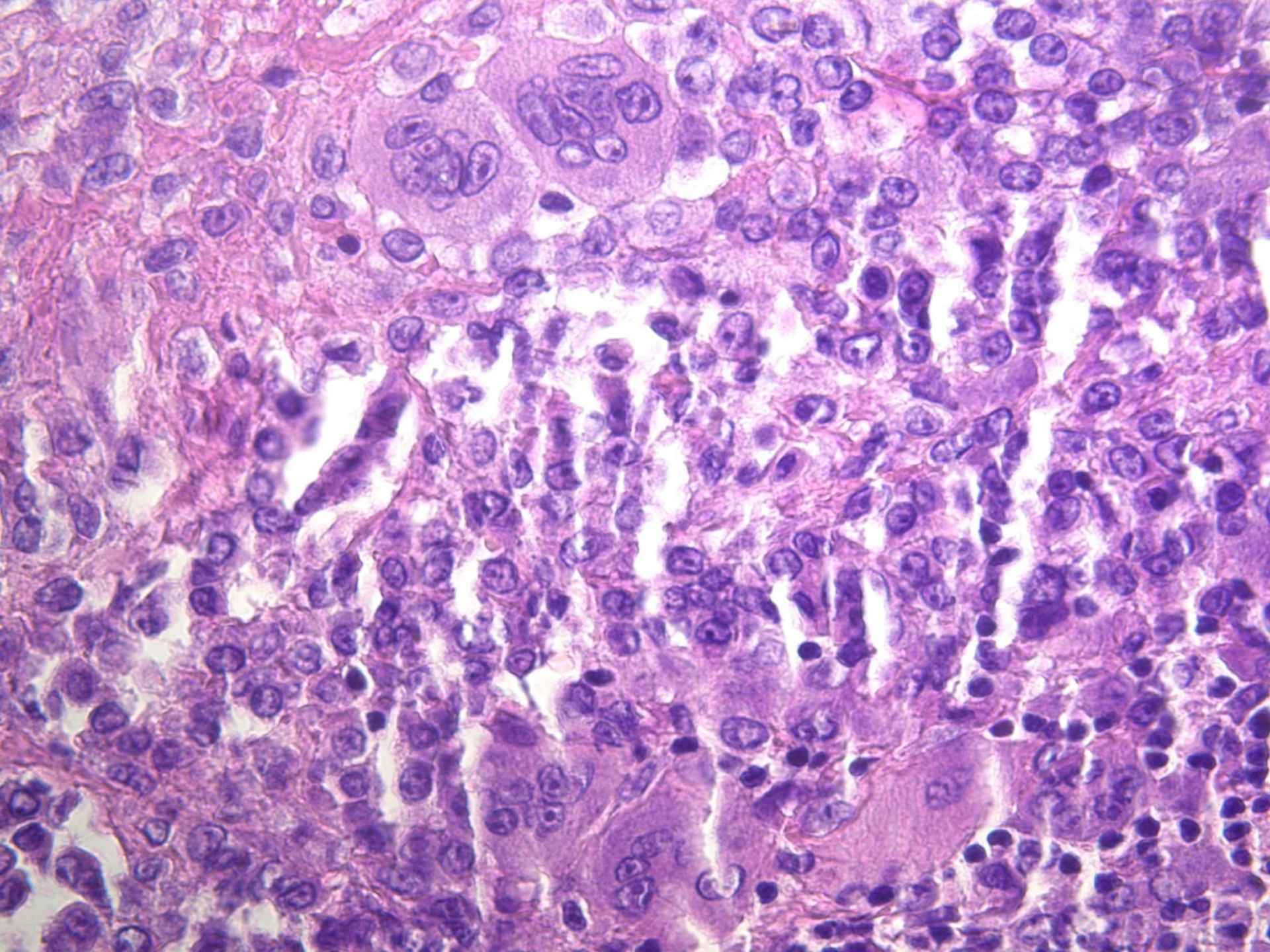


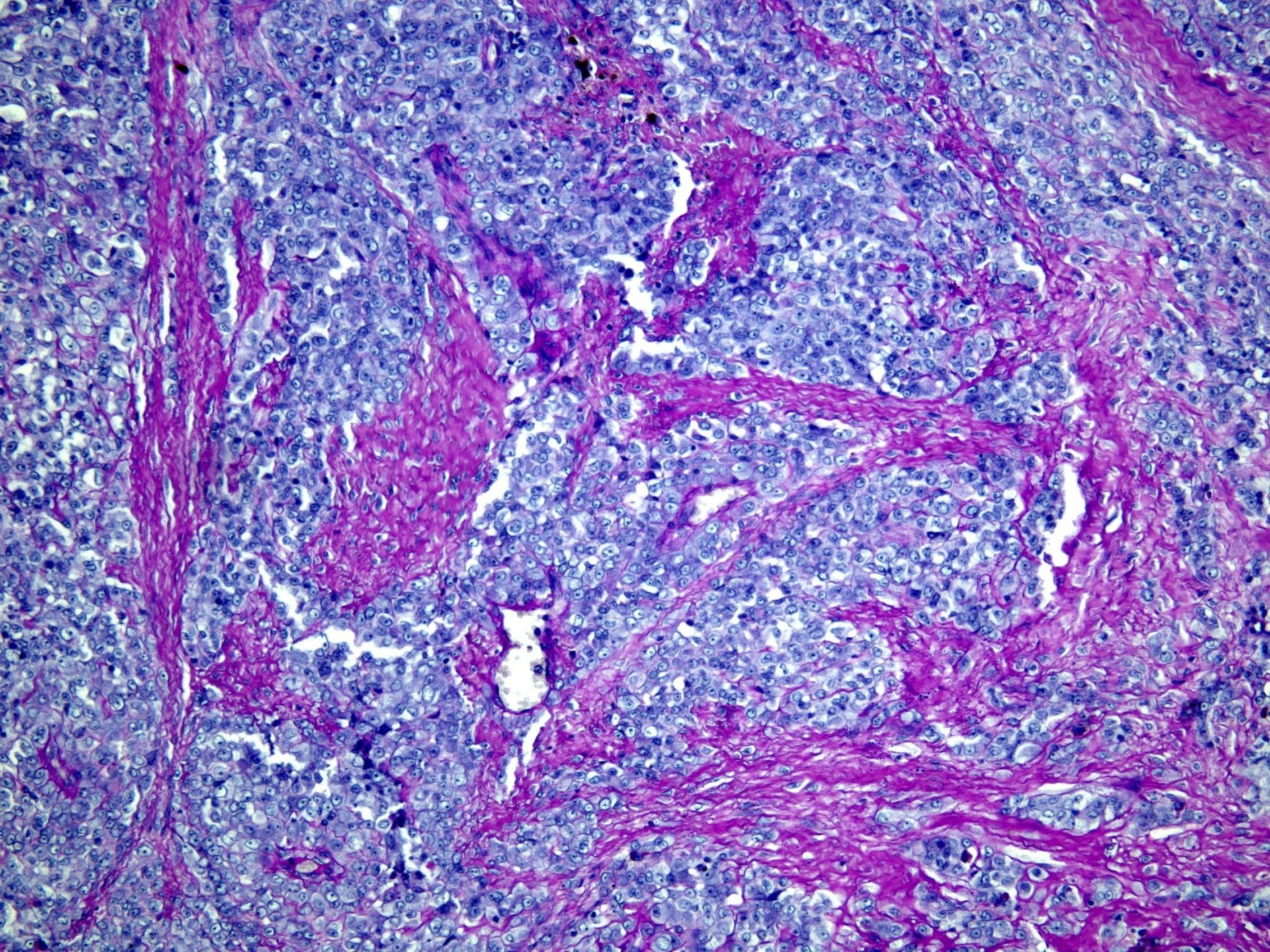


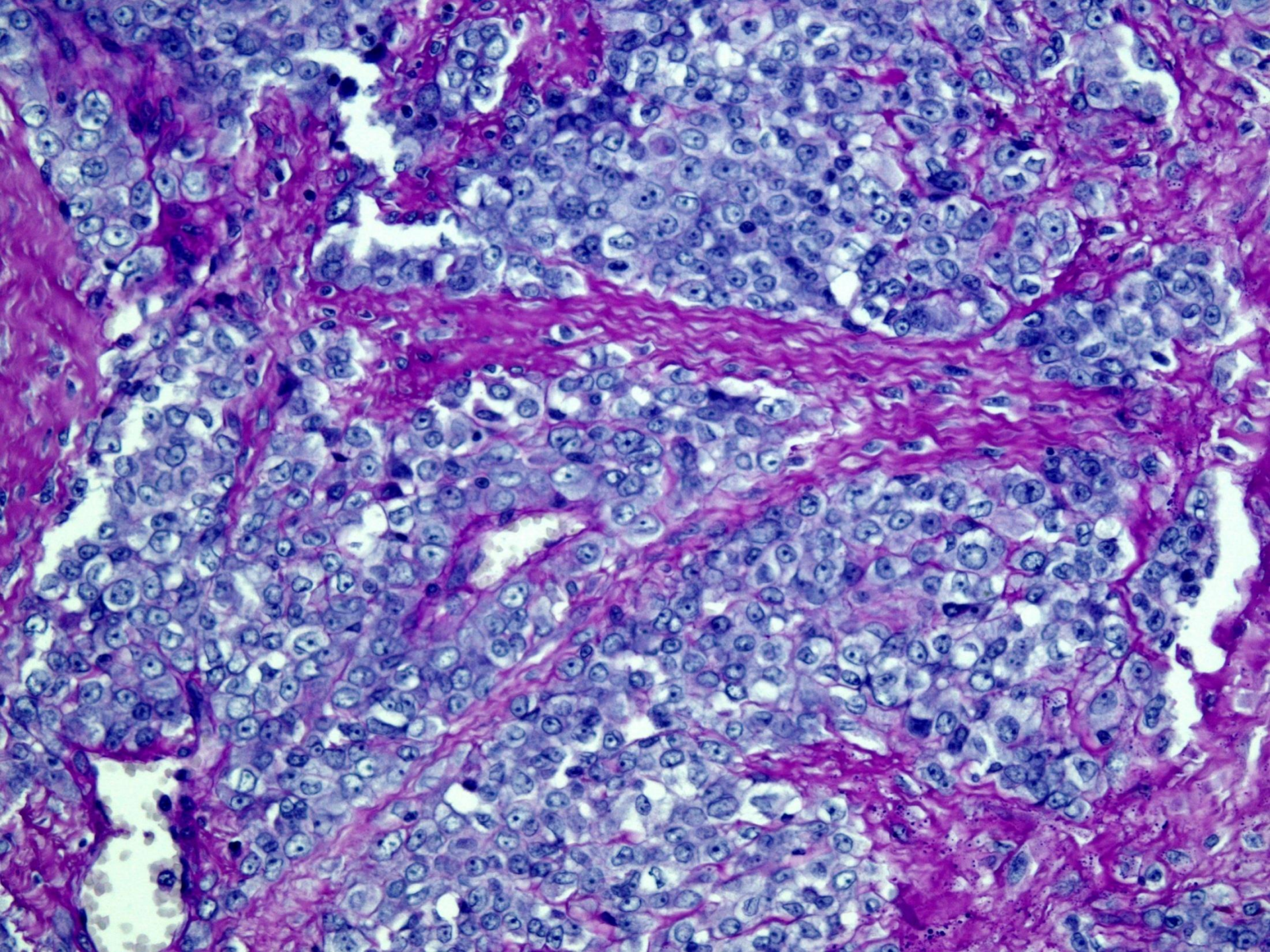


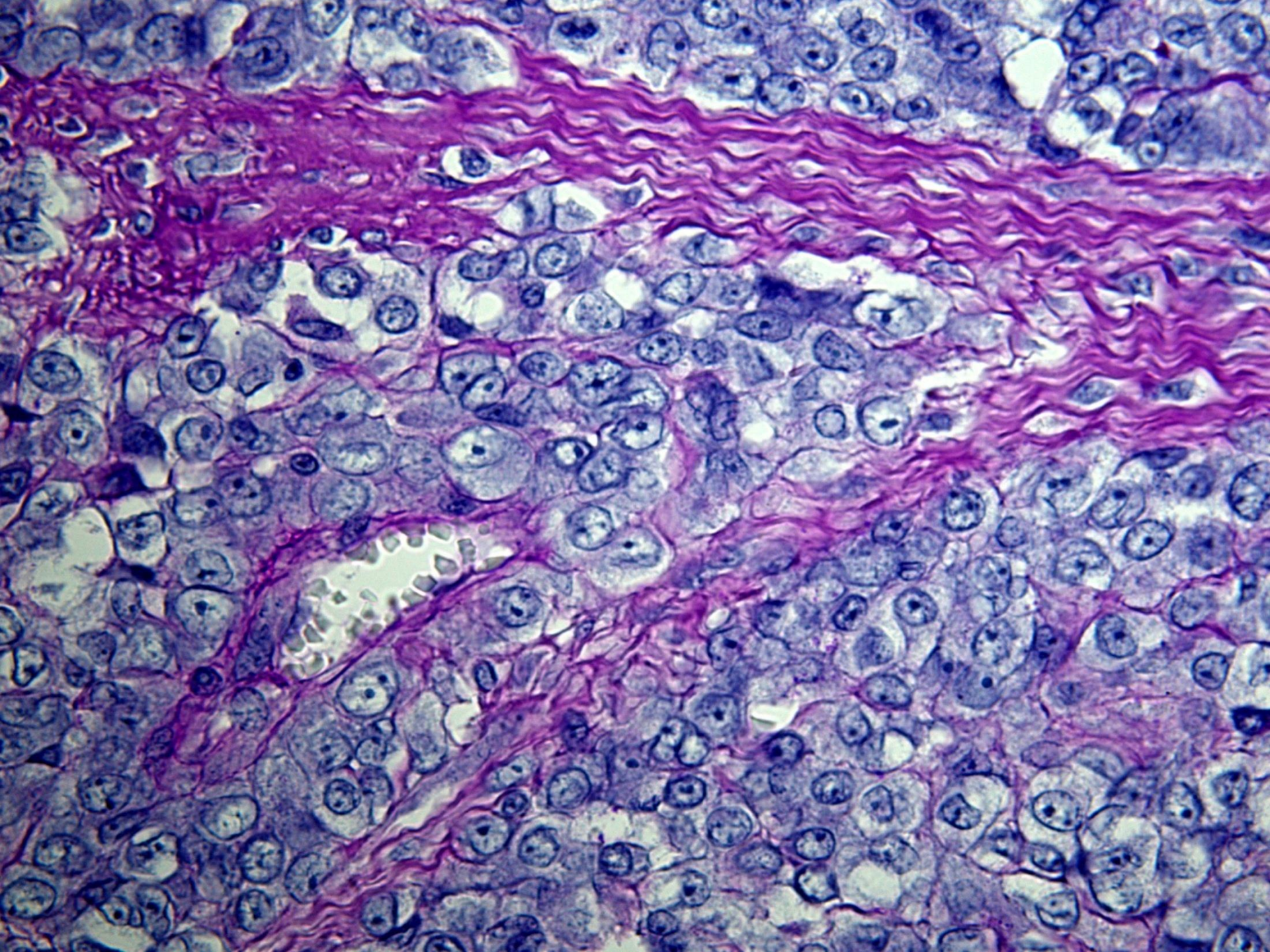


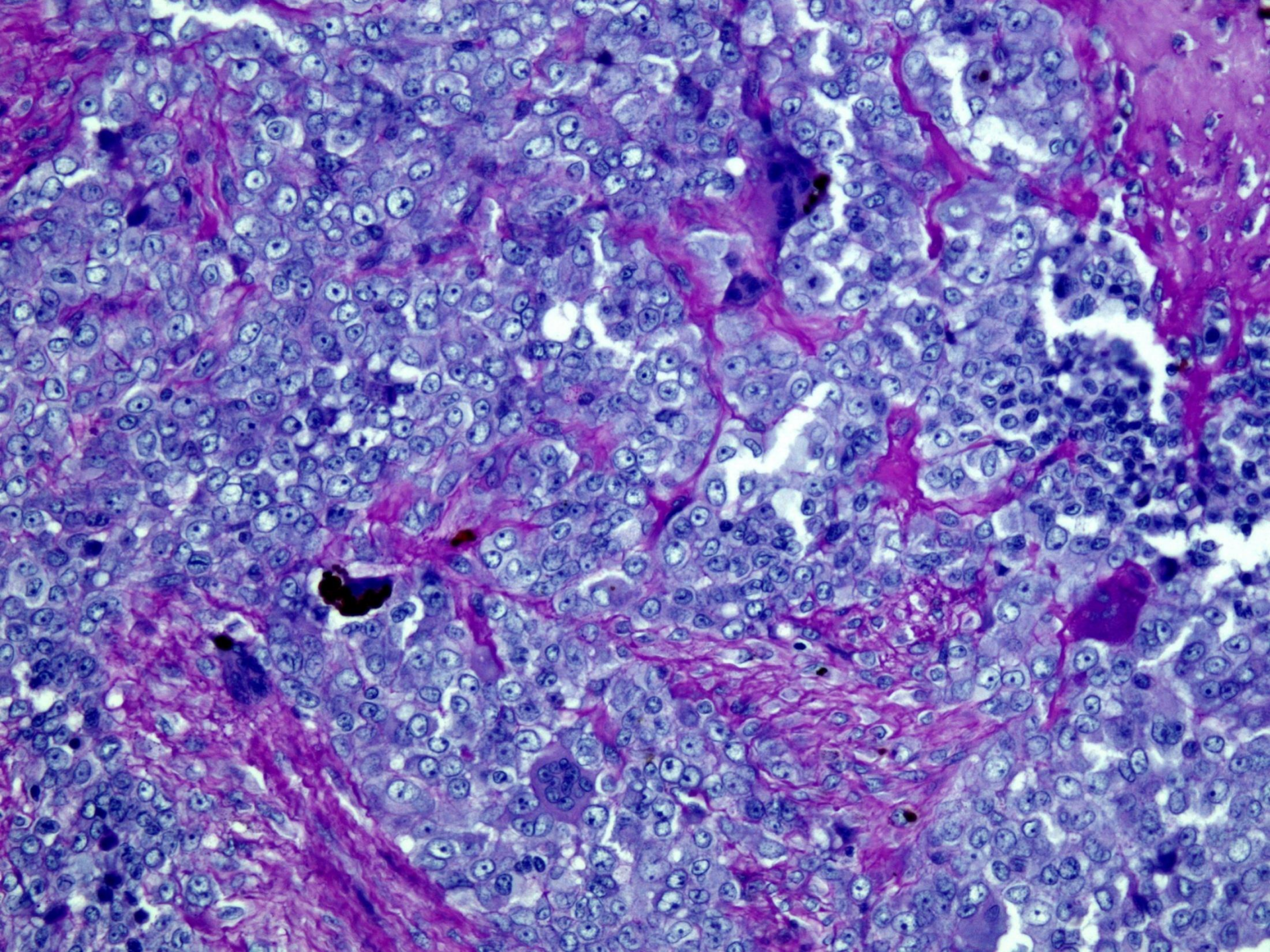


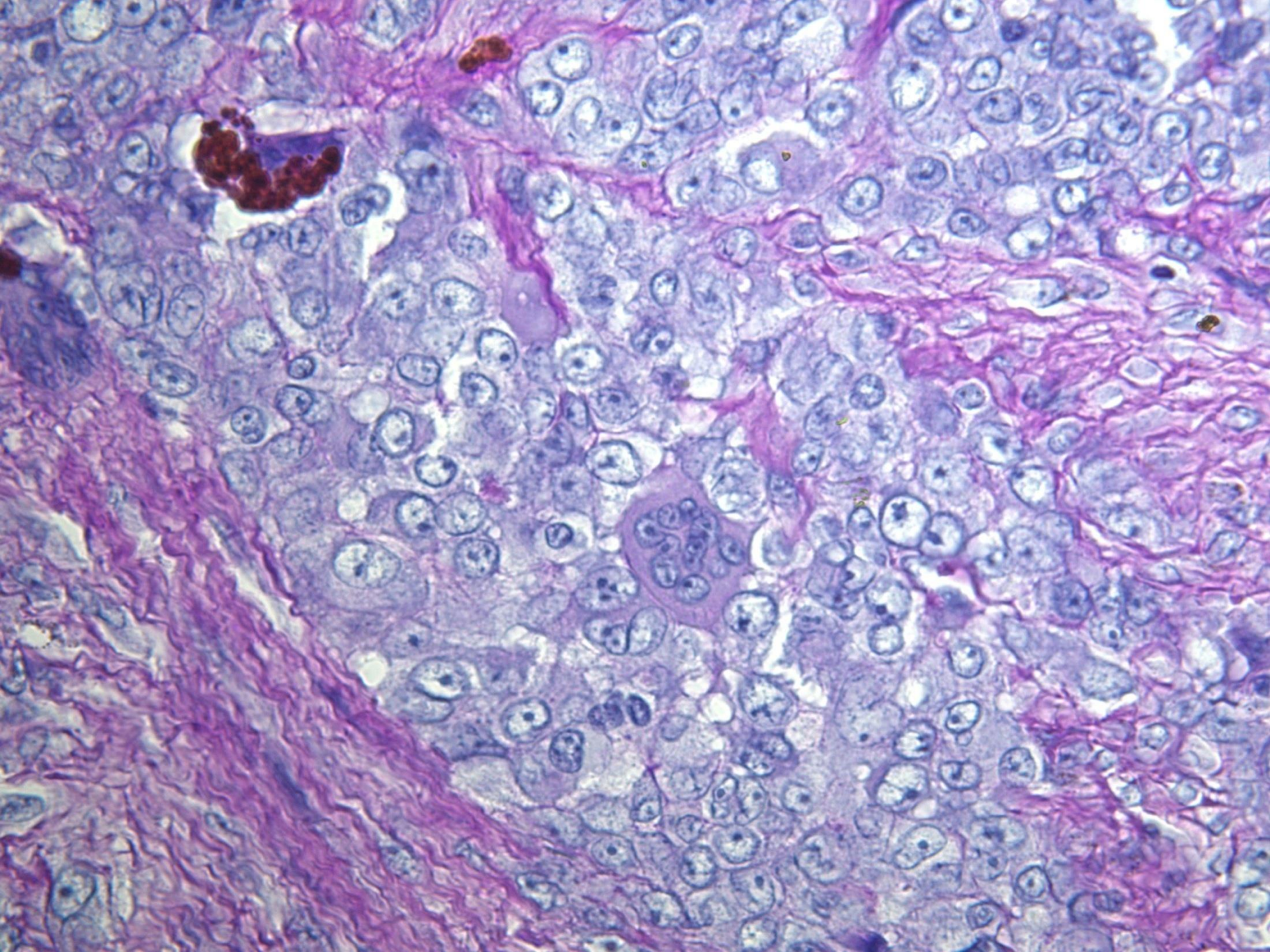


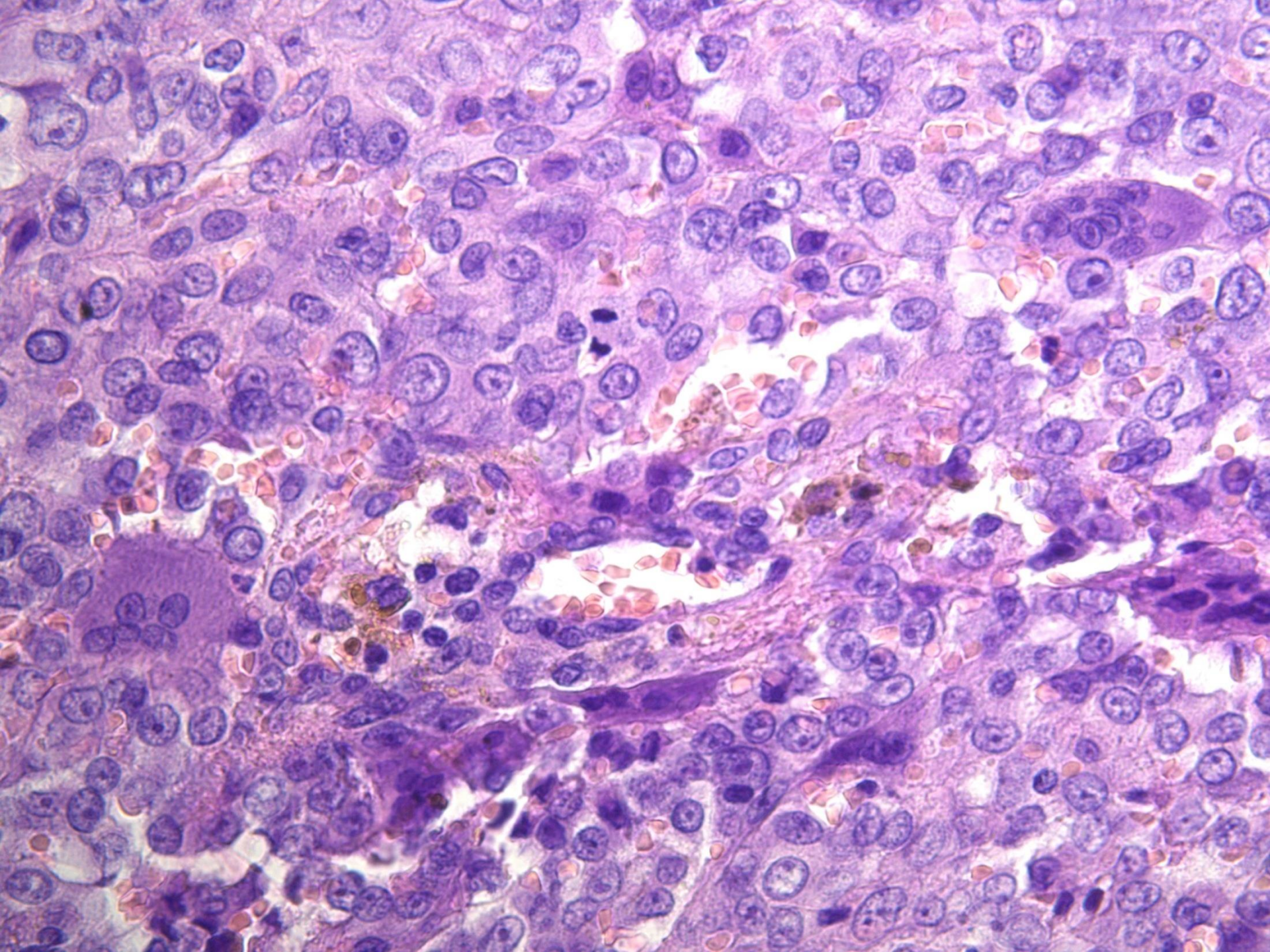


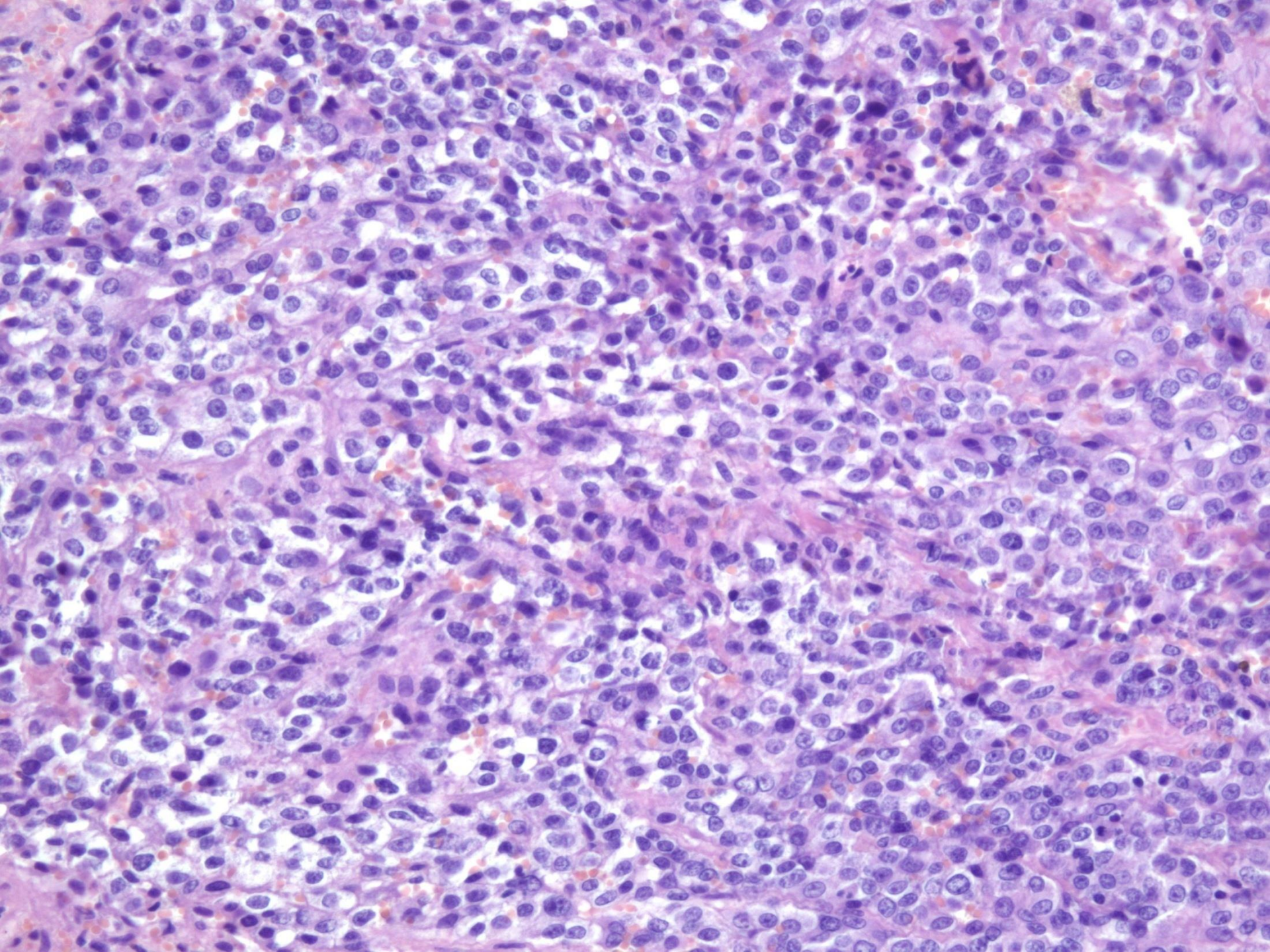


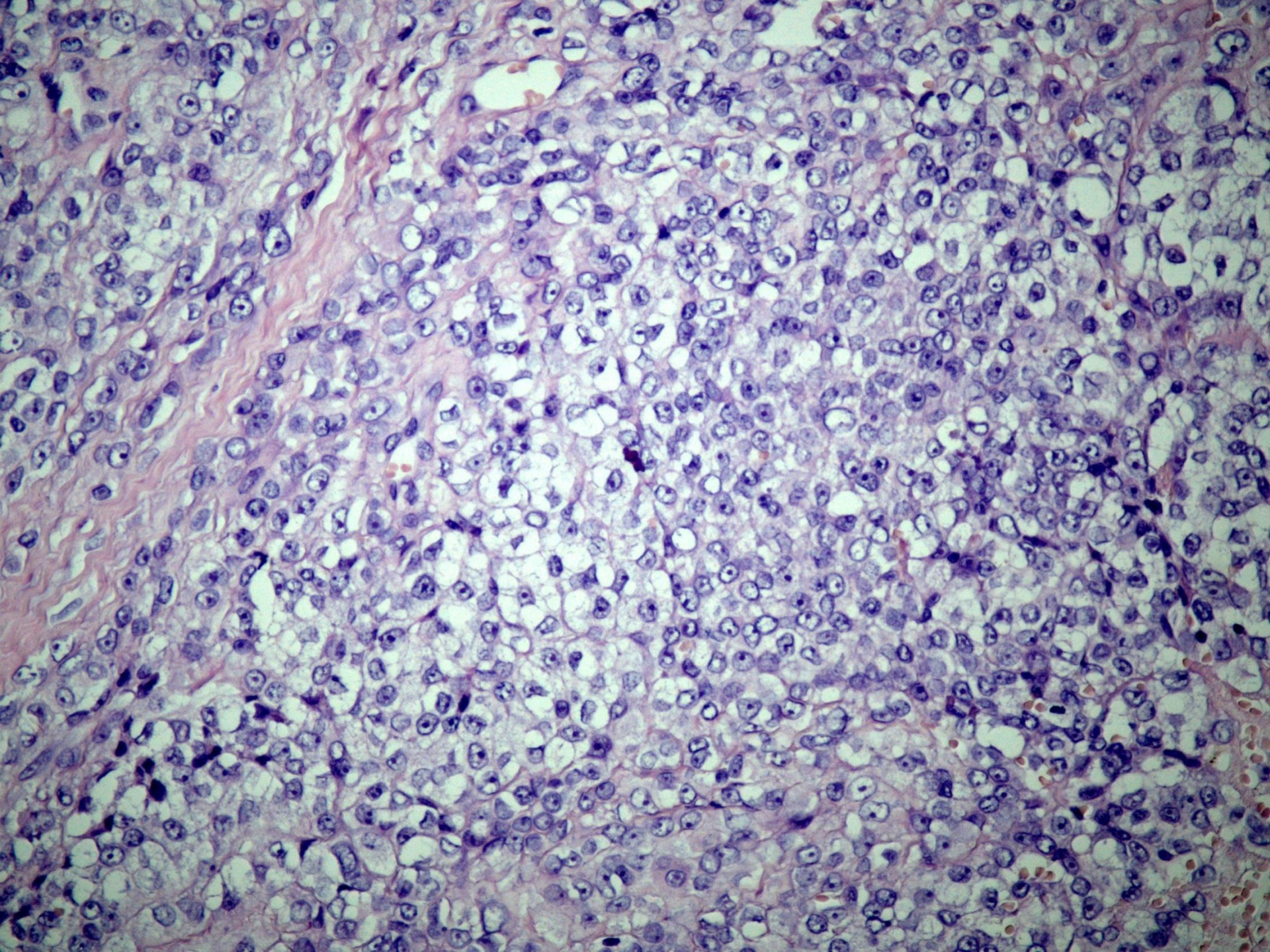


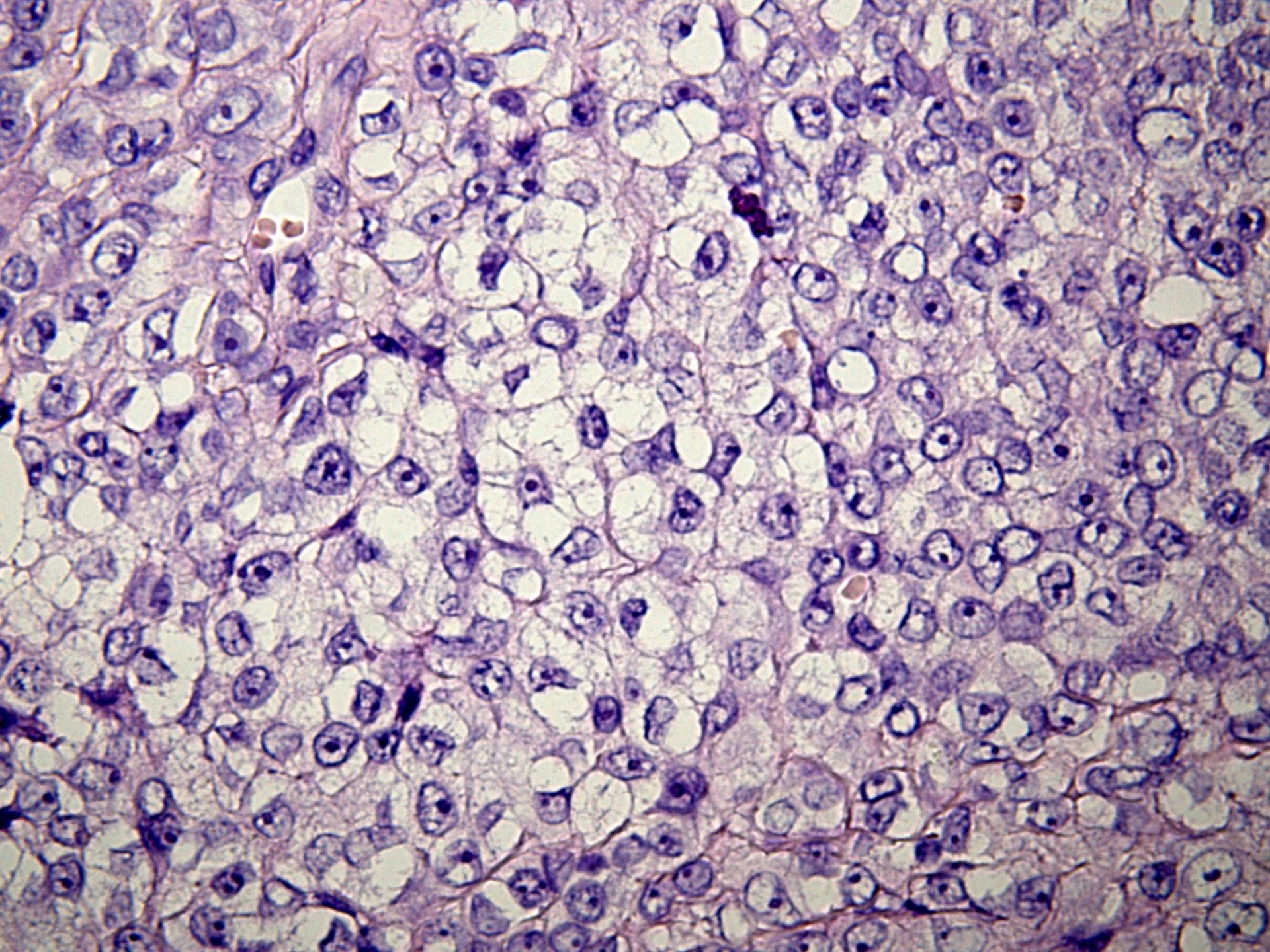


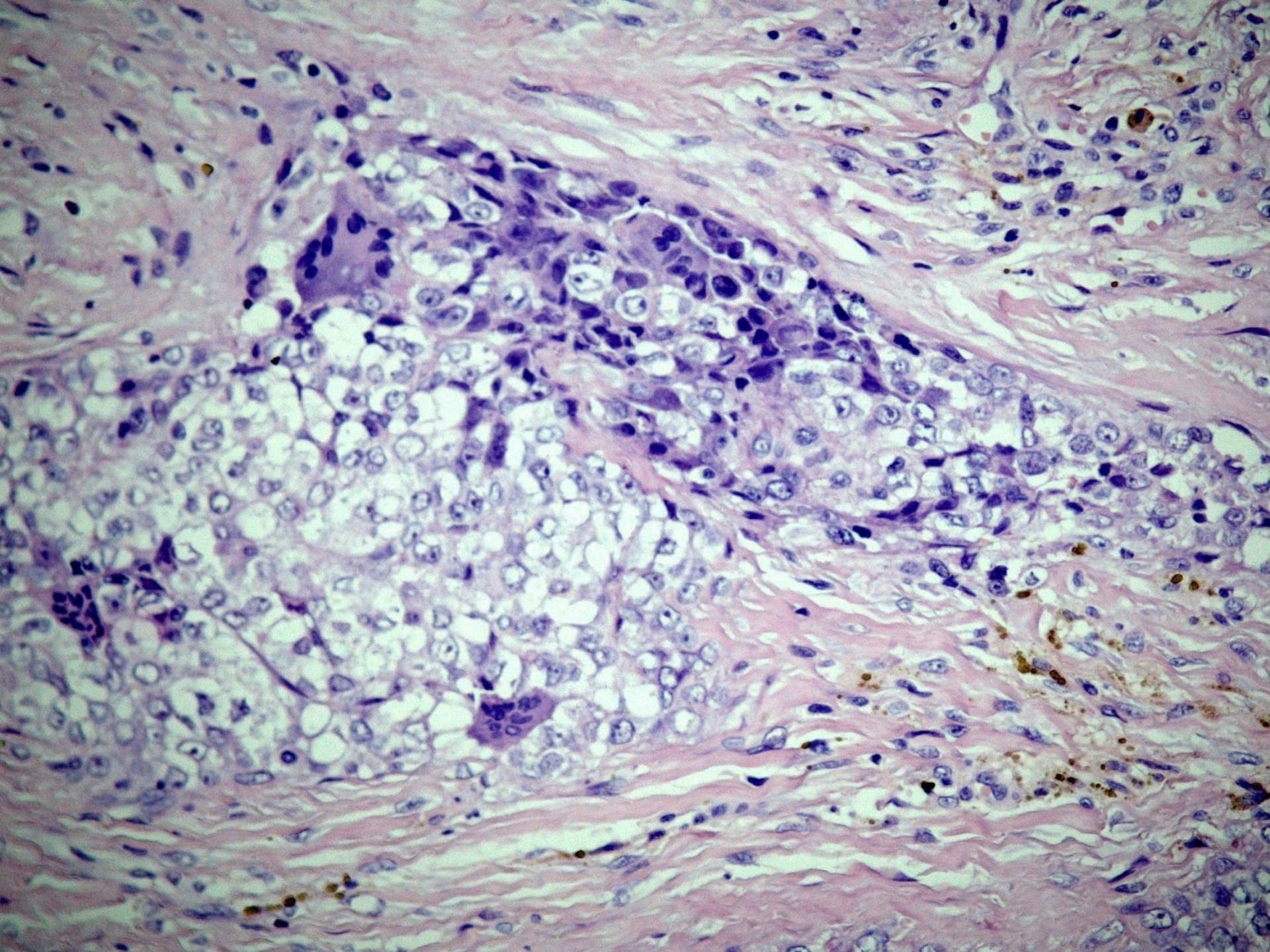






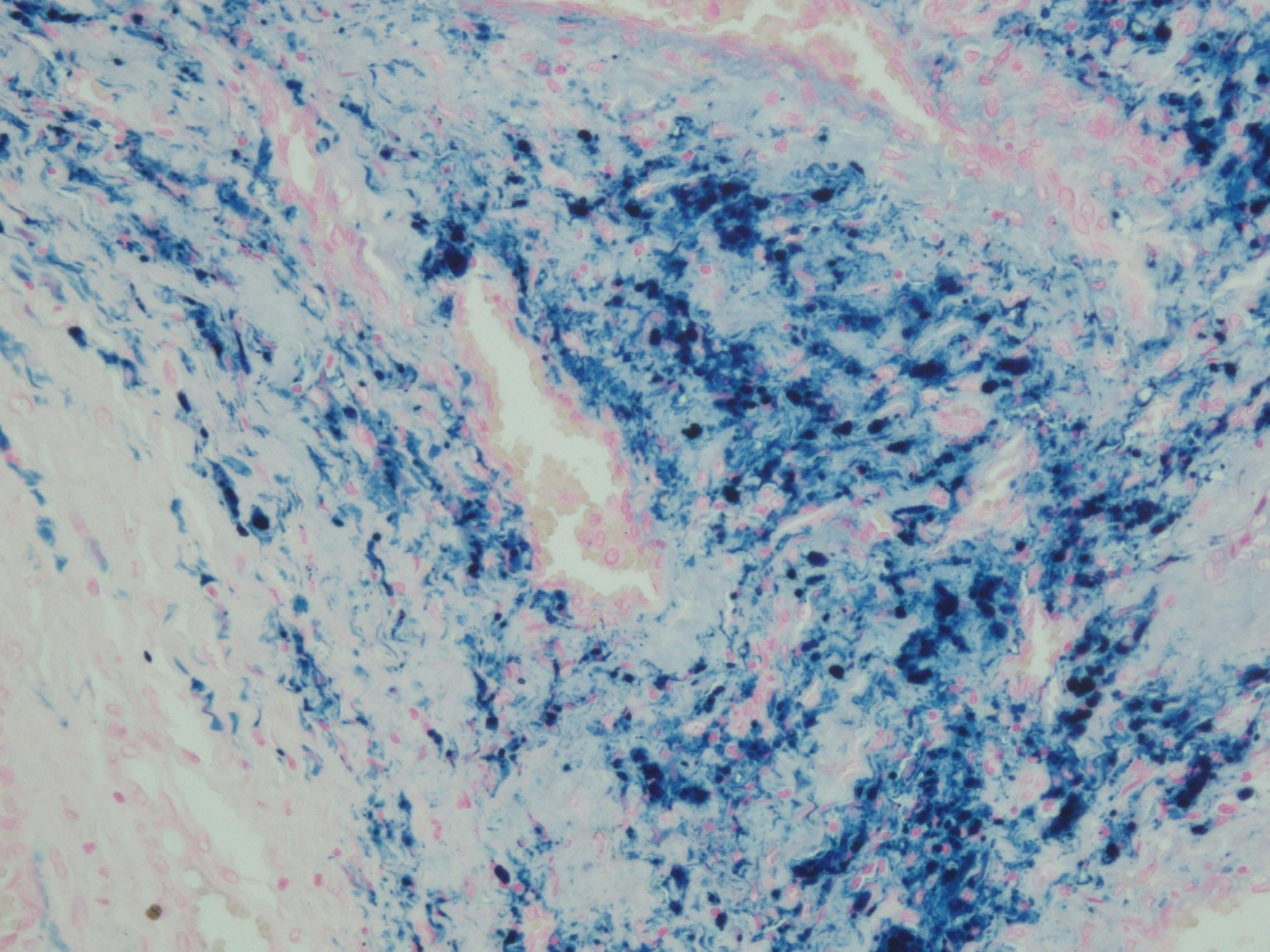


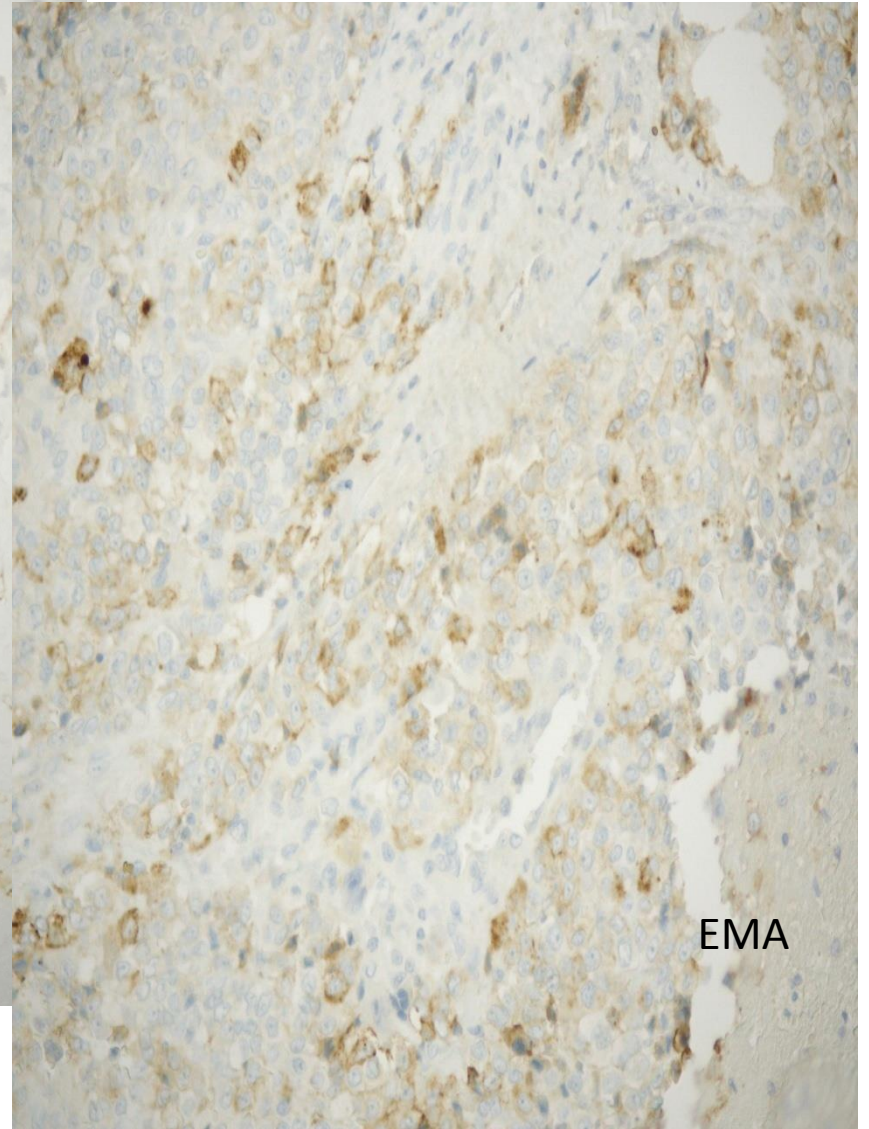
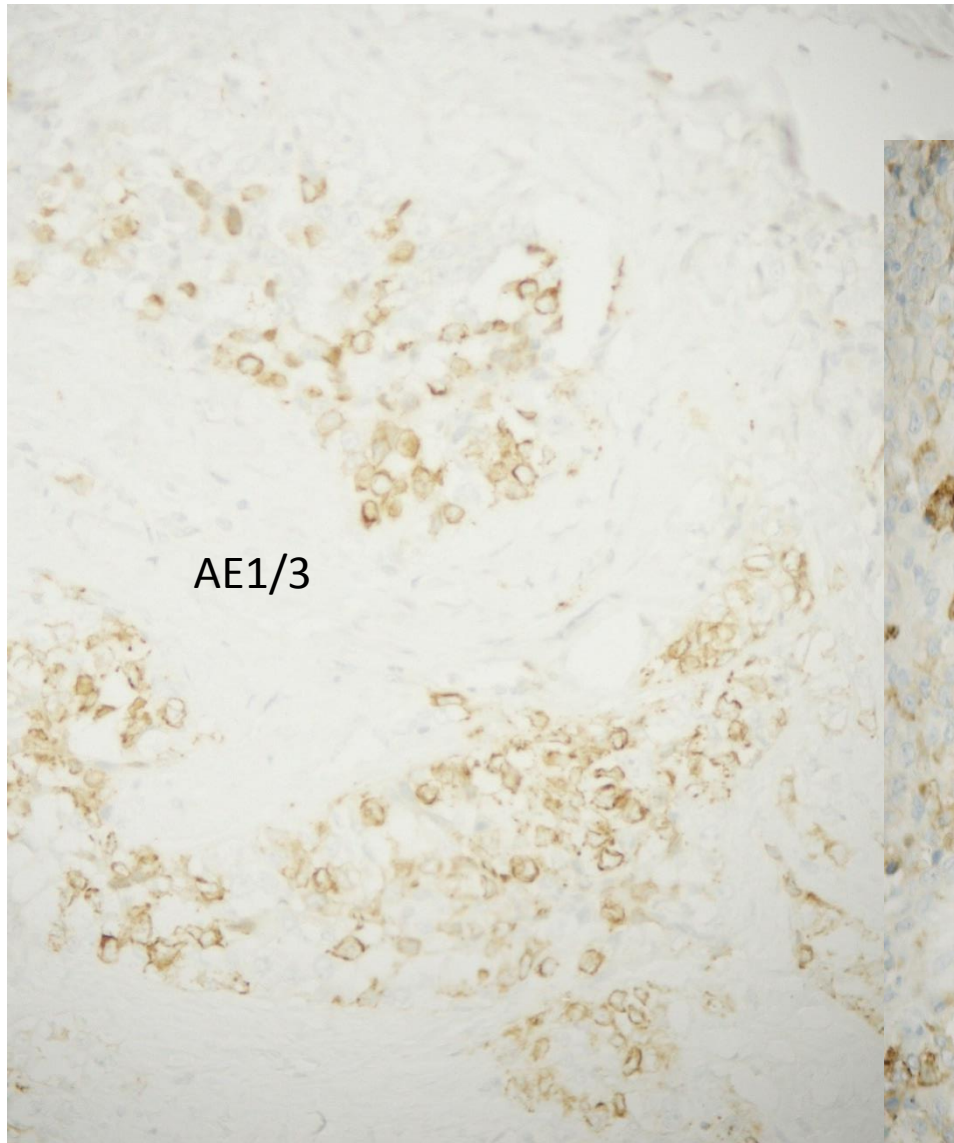


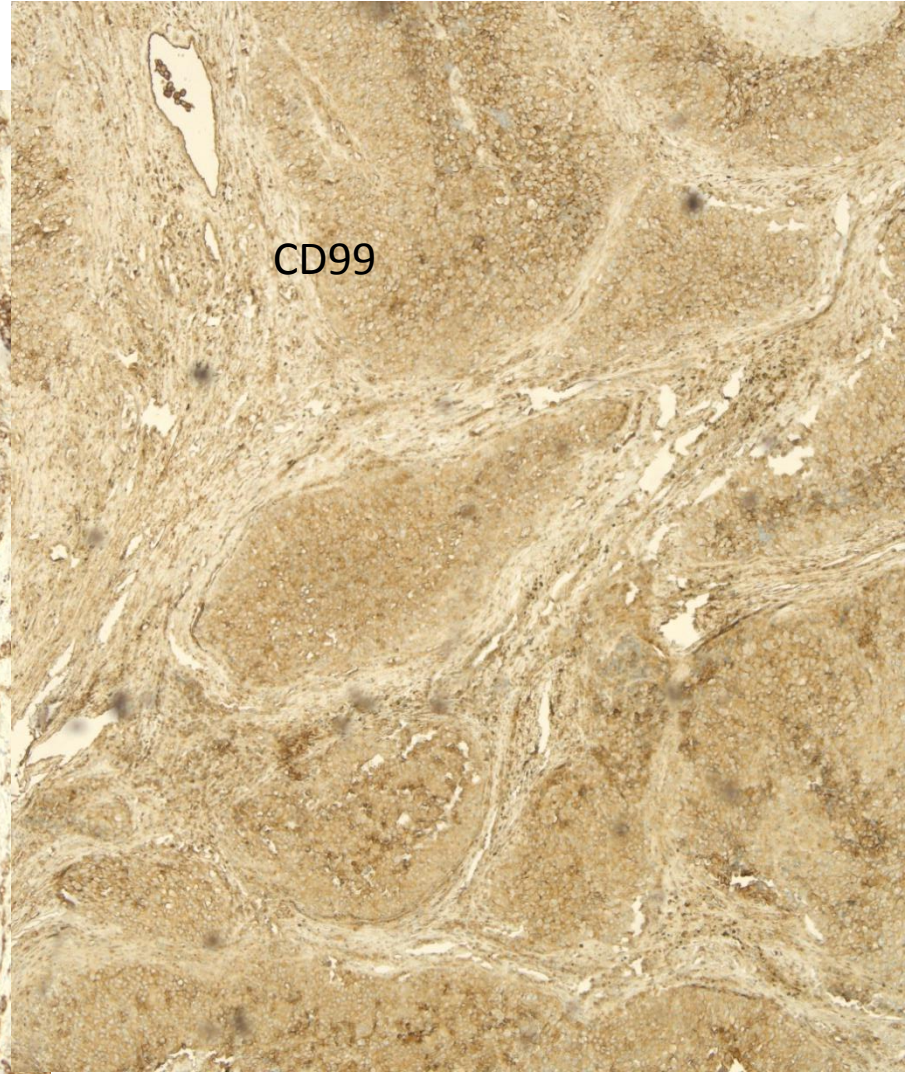
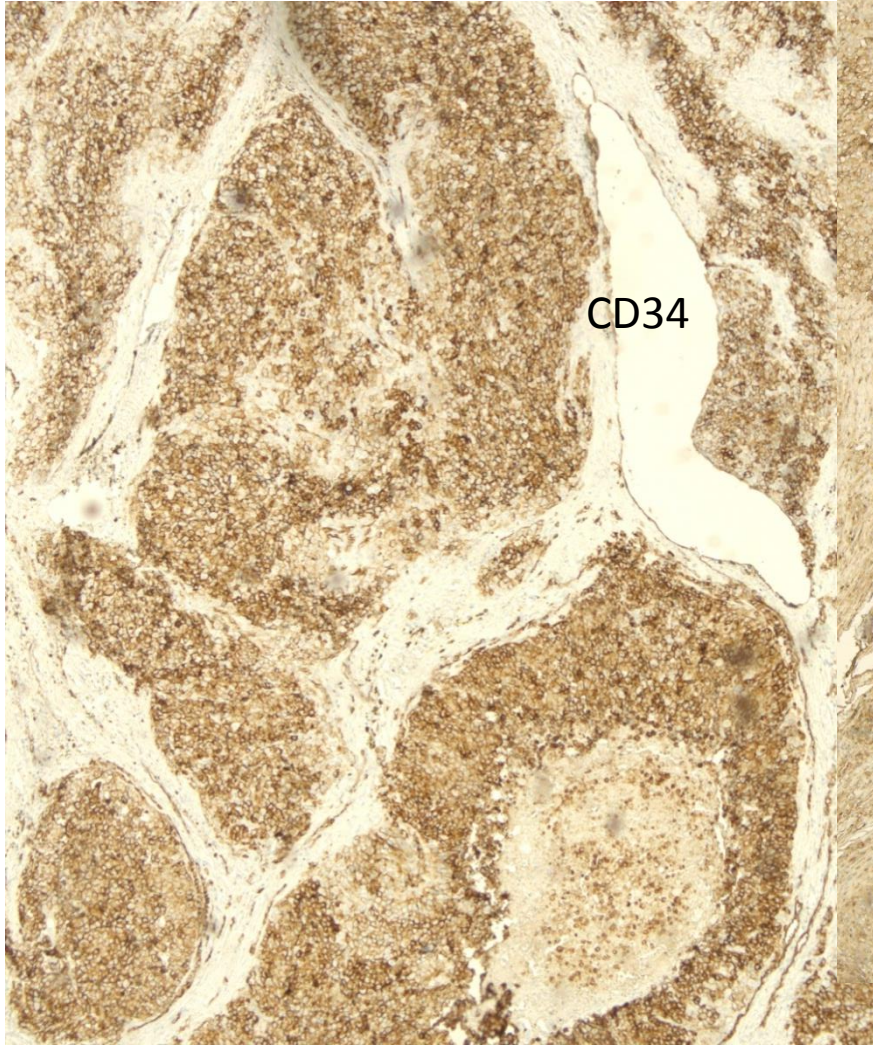


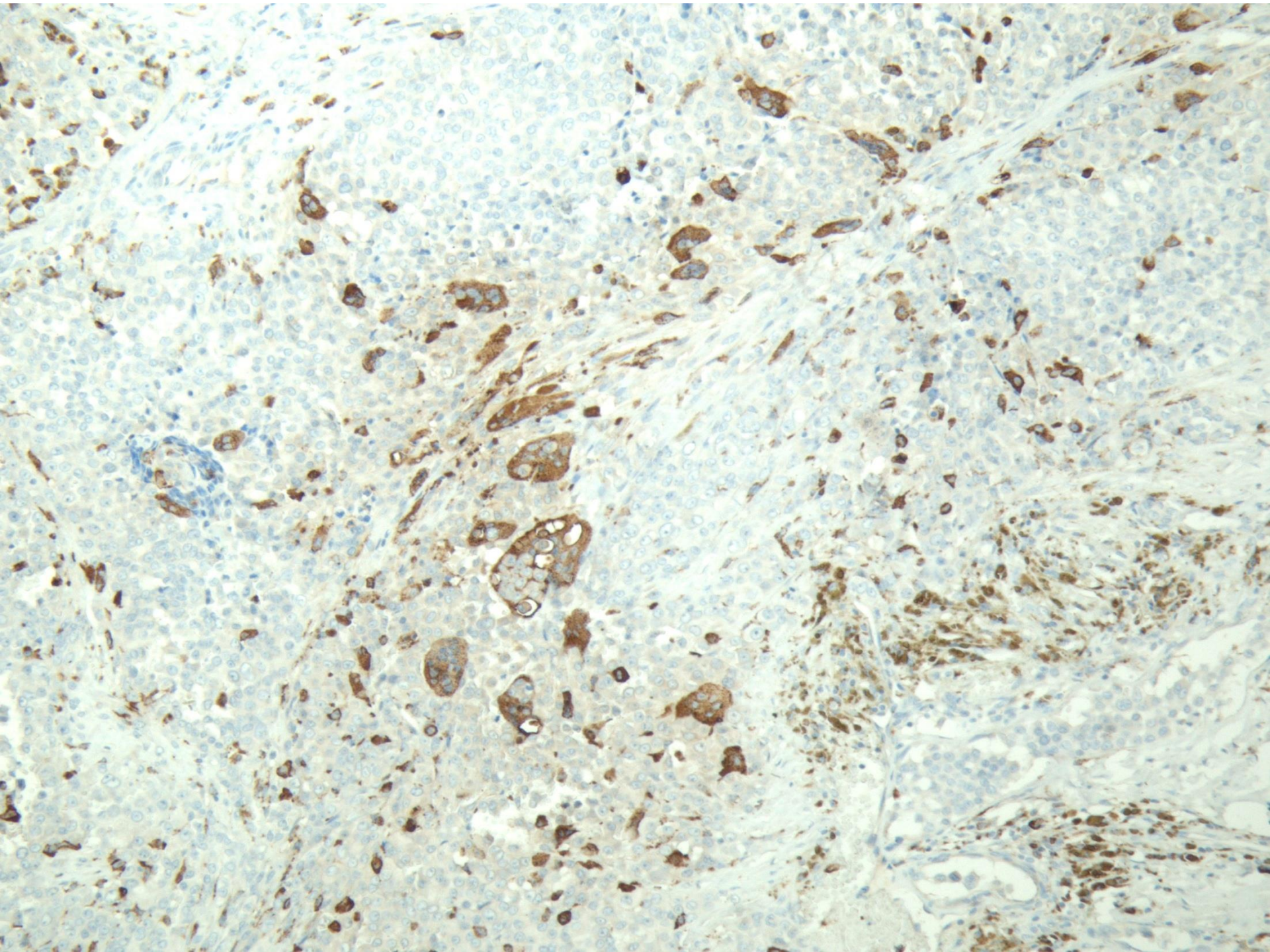
?



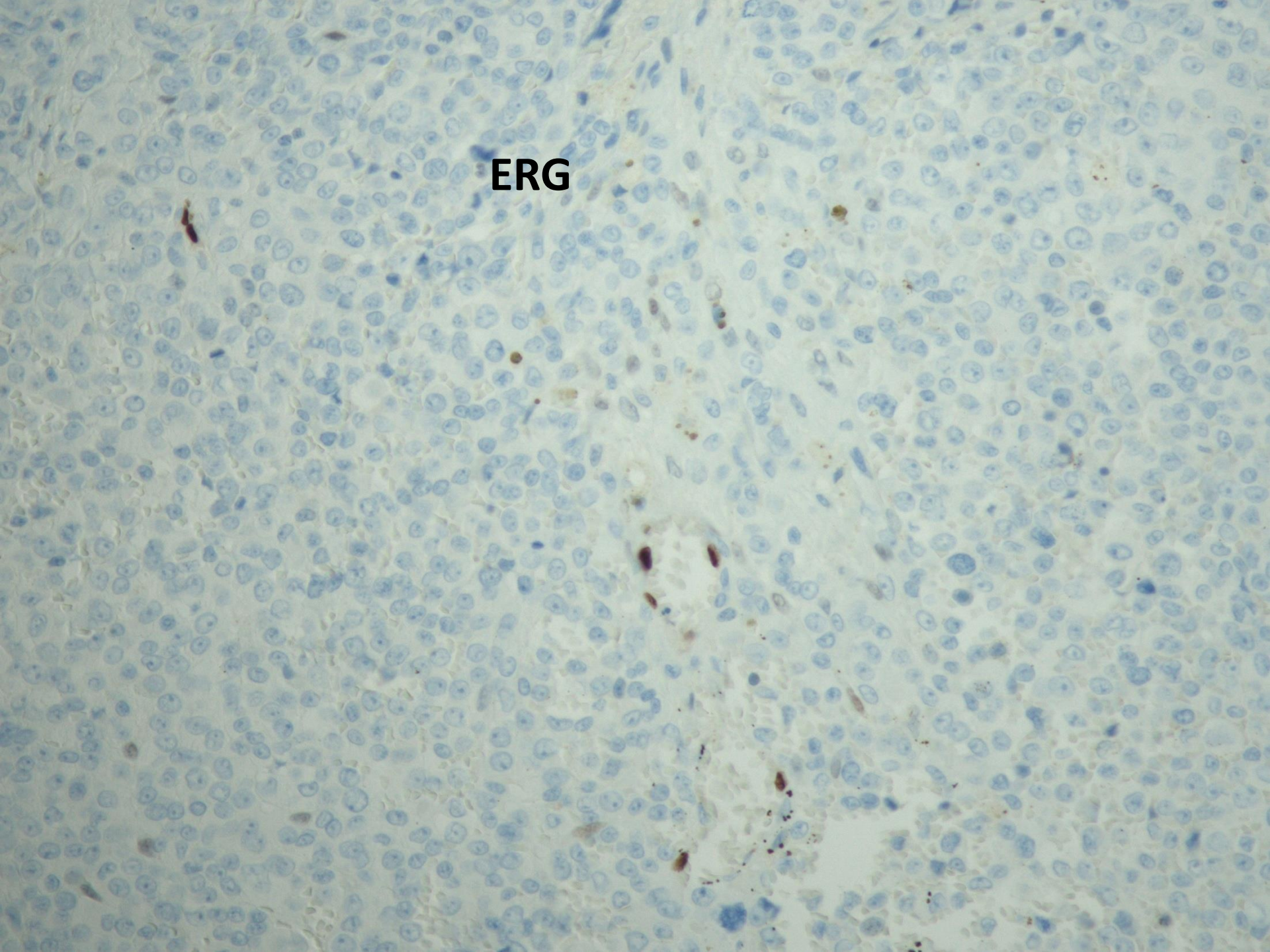


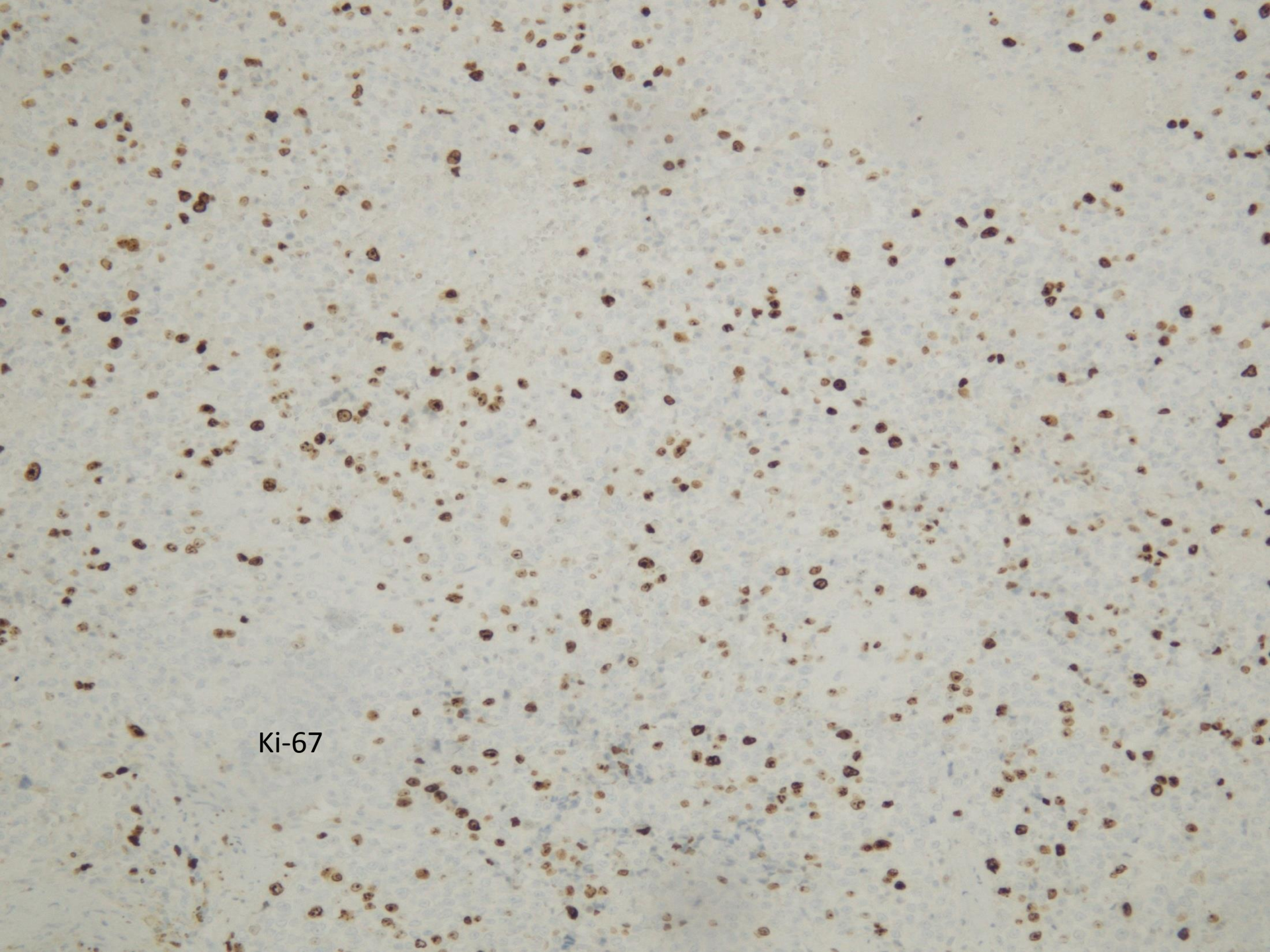






ERG





Ki-67

INI-1

This is a microscopic image of a tissue section, likely a histological slide, stained for the protein INI-1. The image shows a dense population of cells with blue nuclei and brown cytoplasmic staining. The text 'INI-1' is overlaid in the center of the image.



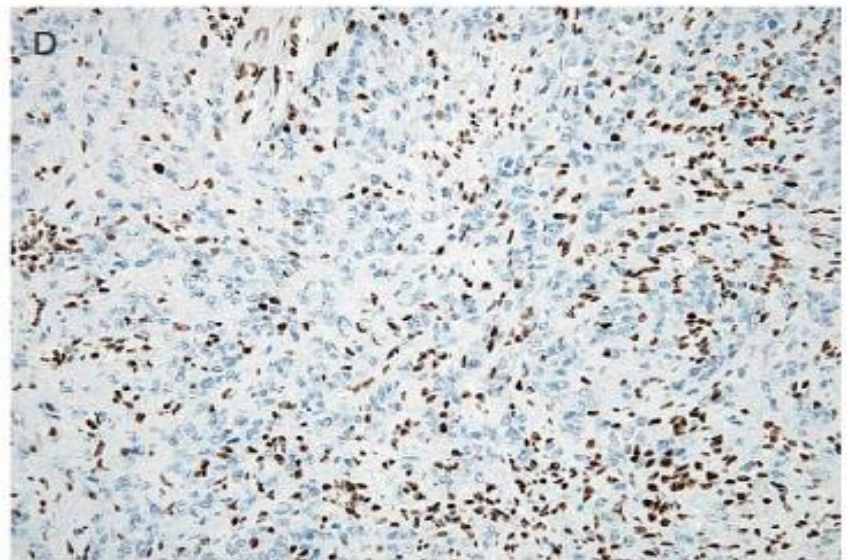
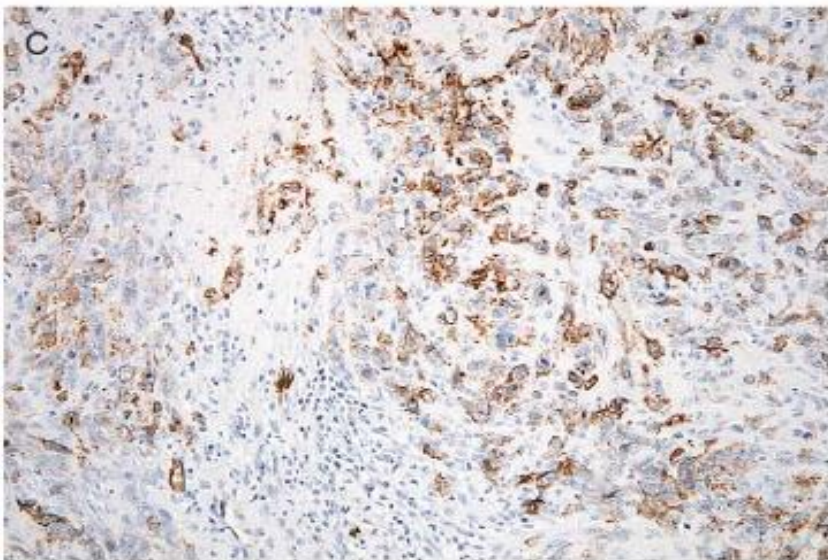
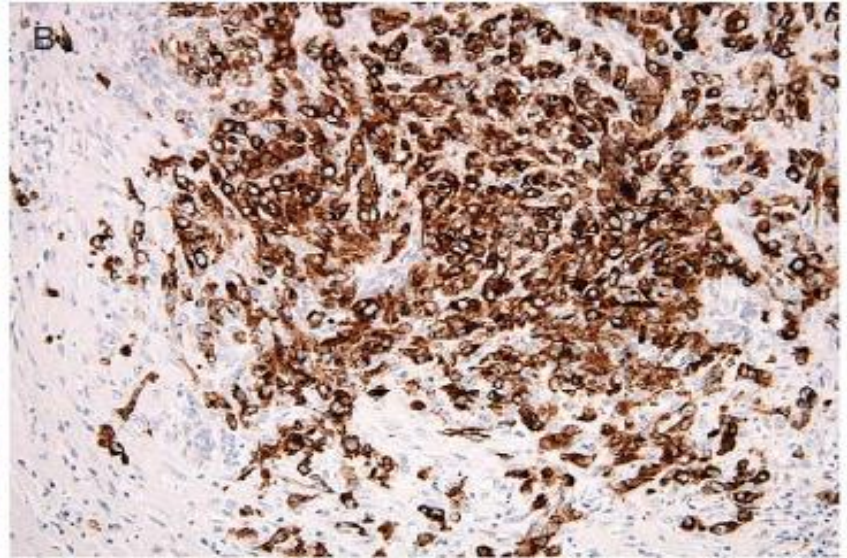
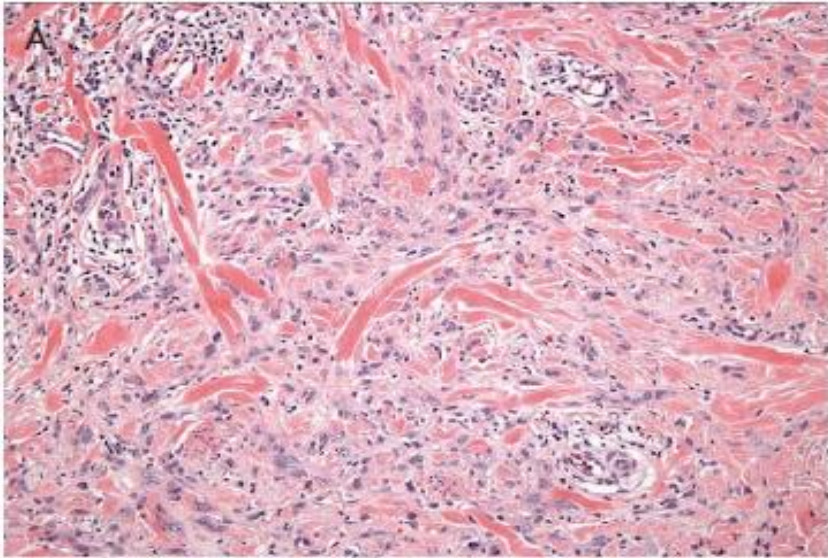
?

Osteoclast-rich, proximal-type
epithelioid sarcoma
(ORPTES)

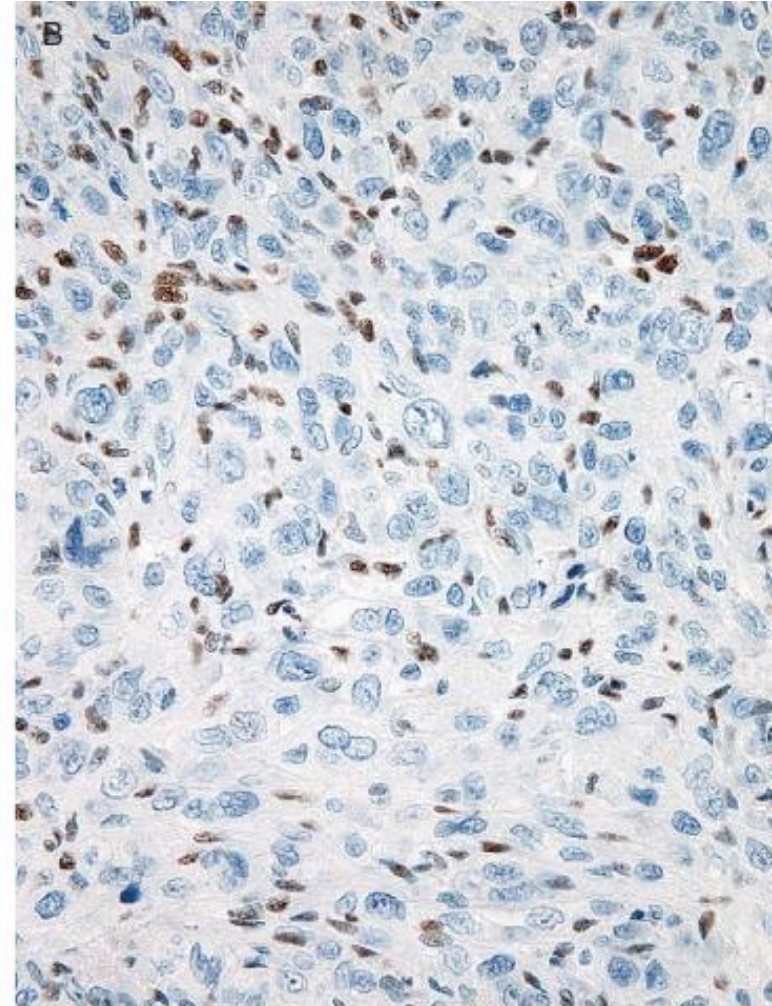
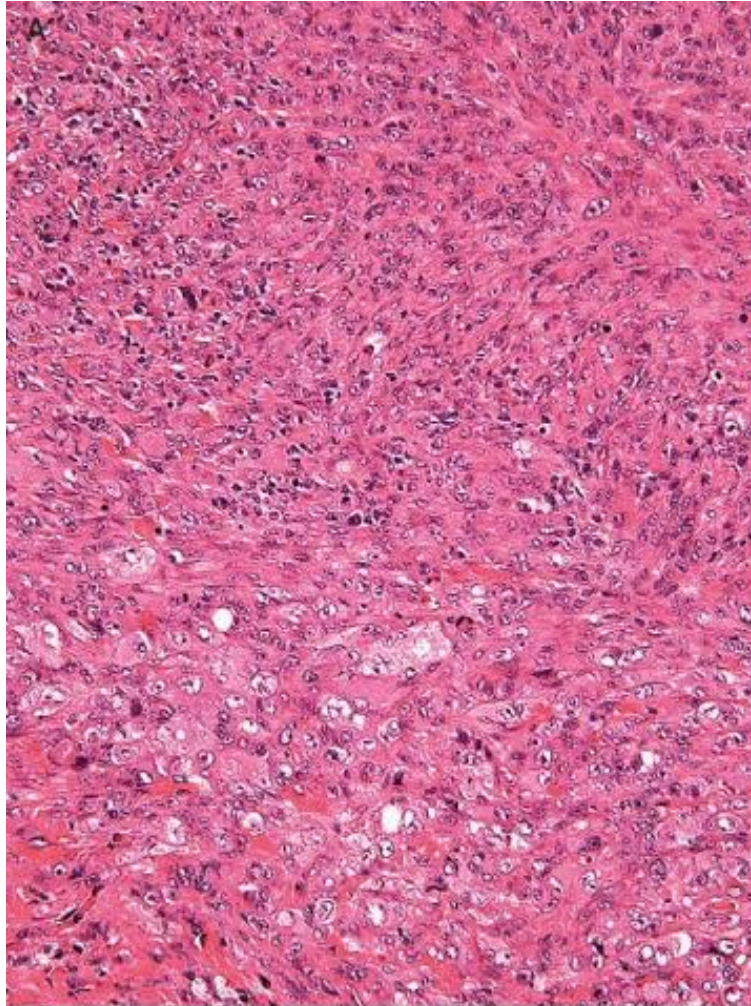
ES-PT

- postihuje starších
- hlboké štruktúry (perineum, inguina)
- „rhabdoidné“ črty
- epiteliálny fenotyp
- nejasná histogenéza
- agresívnejší klinický priebeh

Konvenčný ES



Konvenční a proximální ES



ES

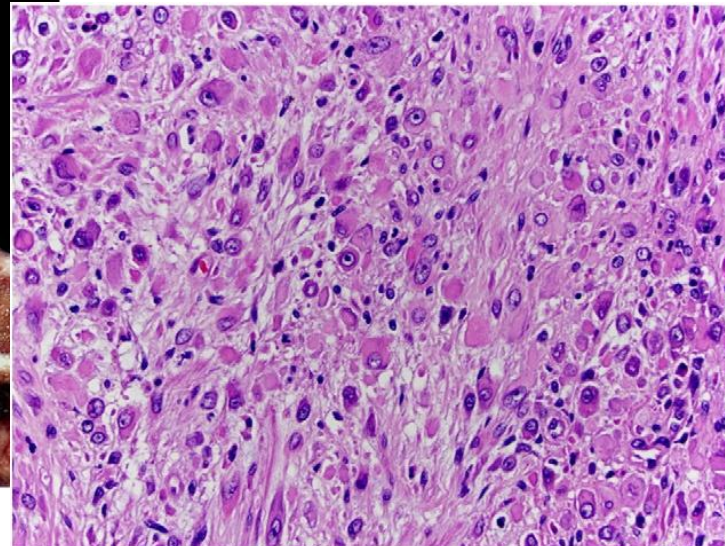
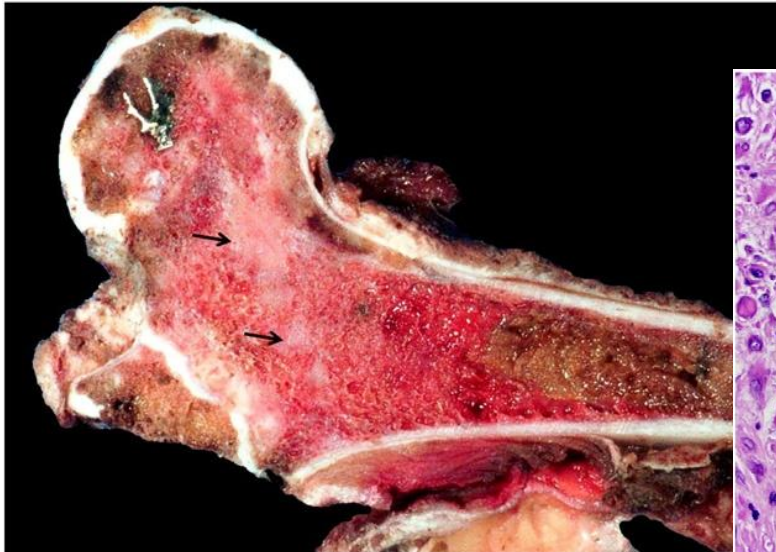
- Delecia INI1 génu na chromozóme 22q11.2
- SMARCB1/INI1-
- AE1/3+, EMA+, CK8+, CK19+, CK5/6-
- CD34+
- ERG+
- Dysadherin+

ES histologické varianty

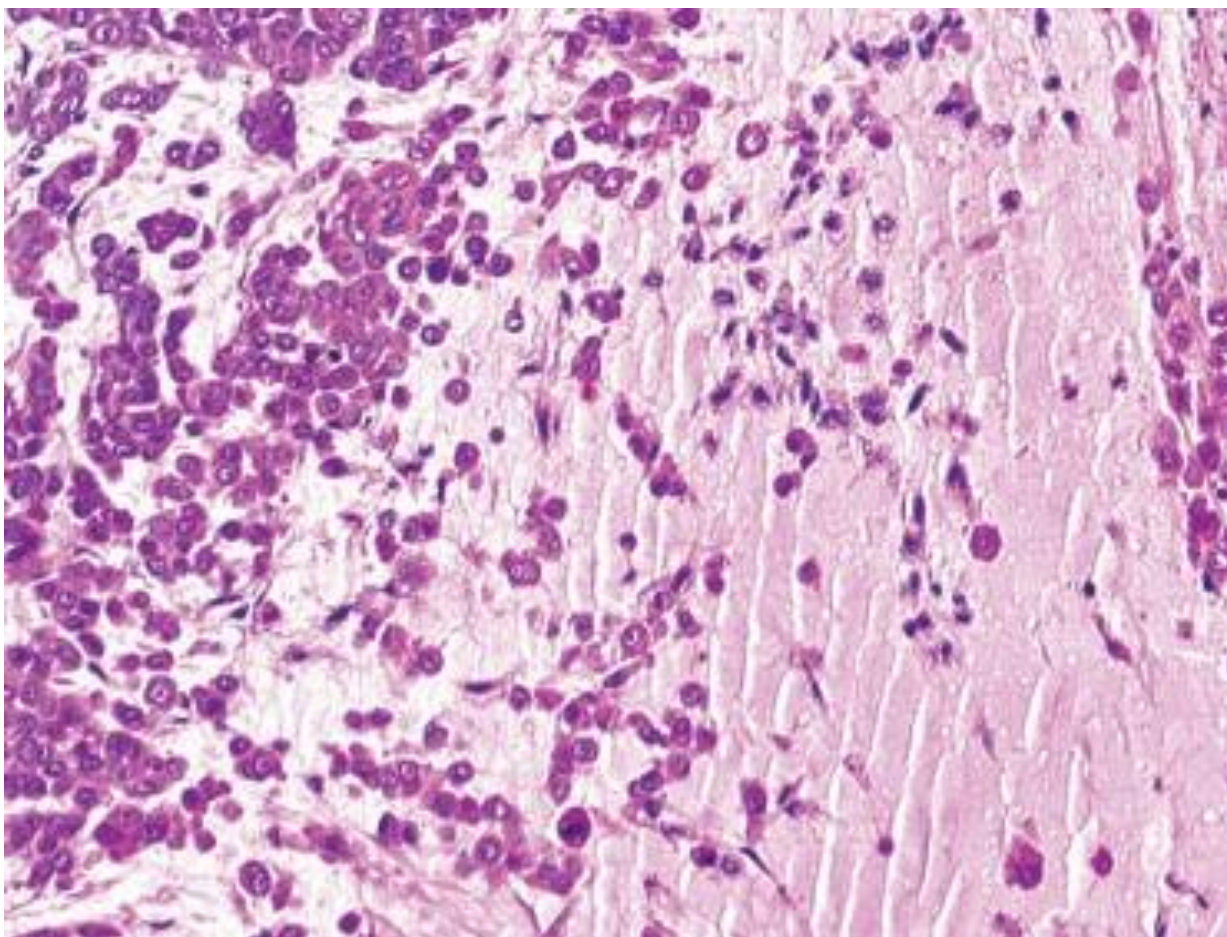
- Angiomatoidný
- (Fibroma-like – PMHE) xxxx
- Myxoidný
- Osteoclast-rich (15 prípadov)

Pseudomyogénny HE (fibroma-like ES)

- t(7;19)(q22;q13)
- SERPINE1-FOSB fúzny gén
- nukleárna FOSB expresia



Myxoidný ES





ELSEVIER

Contents lists available at ScienceDirect

Annals of Diagnostic Pathology



Osteoclast-rich, proximal-type epithelioid sarcoma: clinicopathologic features of 3 unusual cases expanding the histomorphological spectrum



Bharat Rekhi, MD, DNB, MIAC^{a,*}, Anuj Verma, MD^a, Nirmala A. Jambhekar, MD, DPB^a, Santosh Menon, MD, DNB^a, Siddhartha Laskar, MD, DNB^b, Nikhil Merchant, MD^c, Neha Mittal, MD, DNB^a, Ajay Puri, MS^d

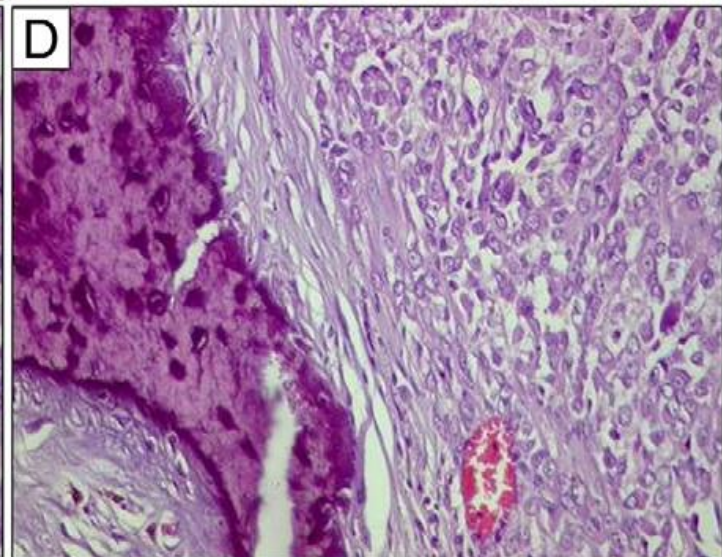
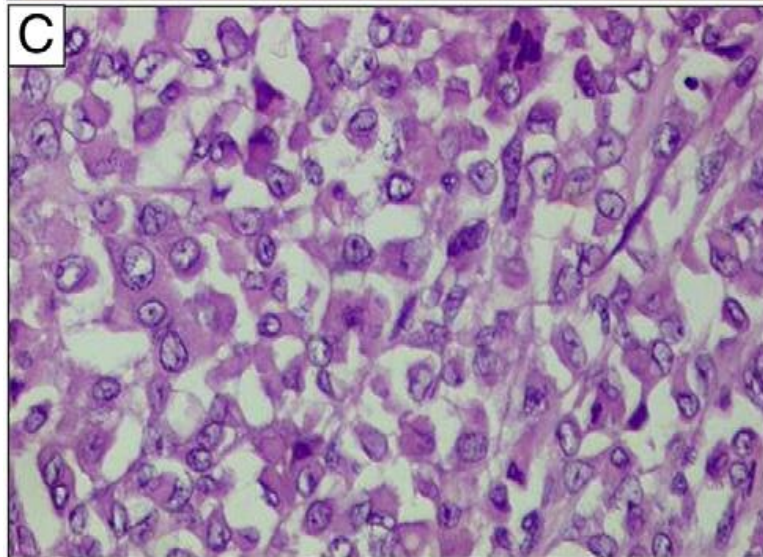
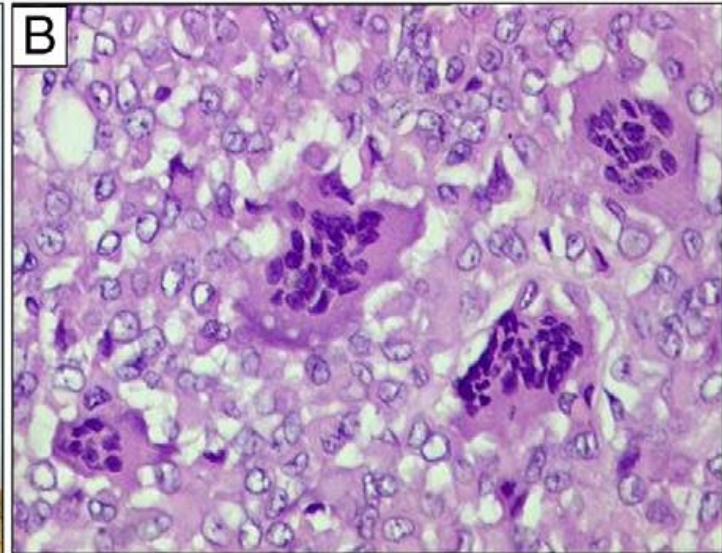
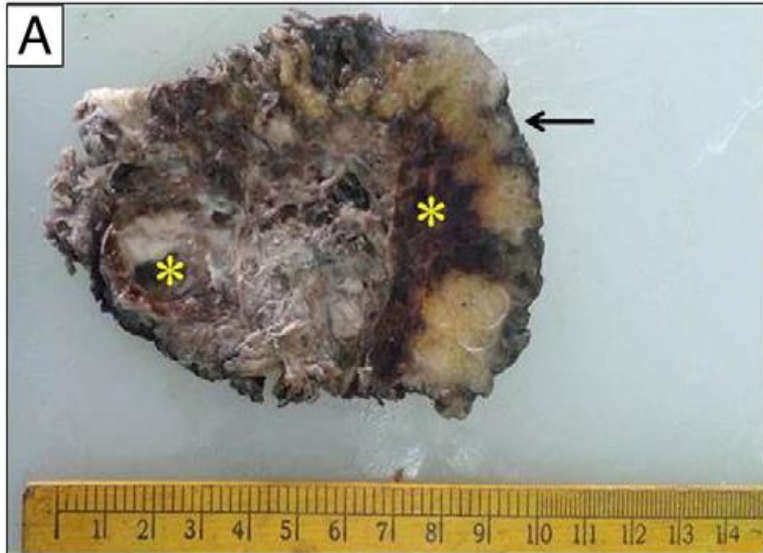
^a Department of Surgical Pathology, Tata Memorial Centre, Mumbai, Maharashtra, India

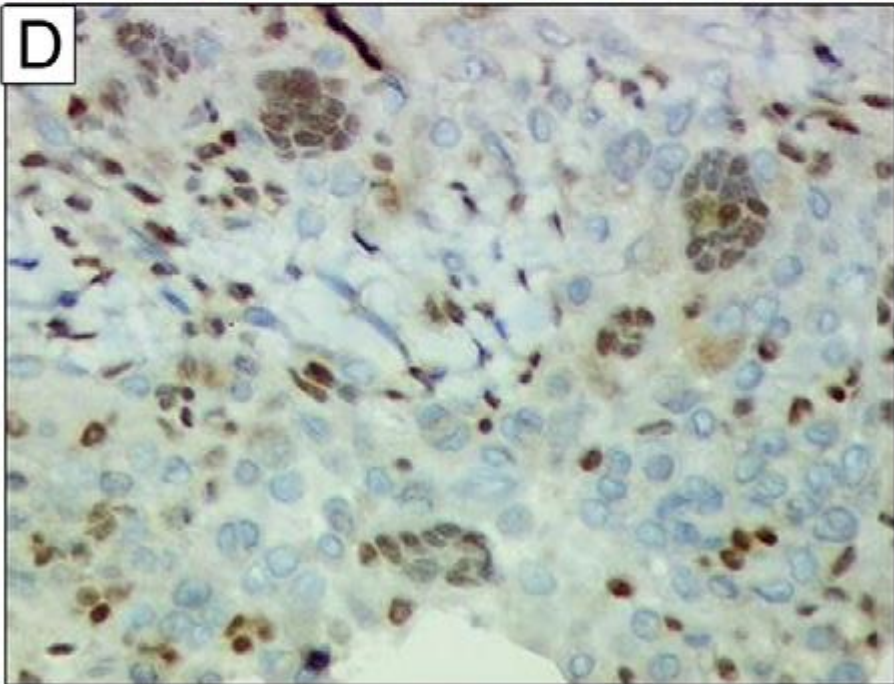
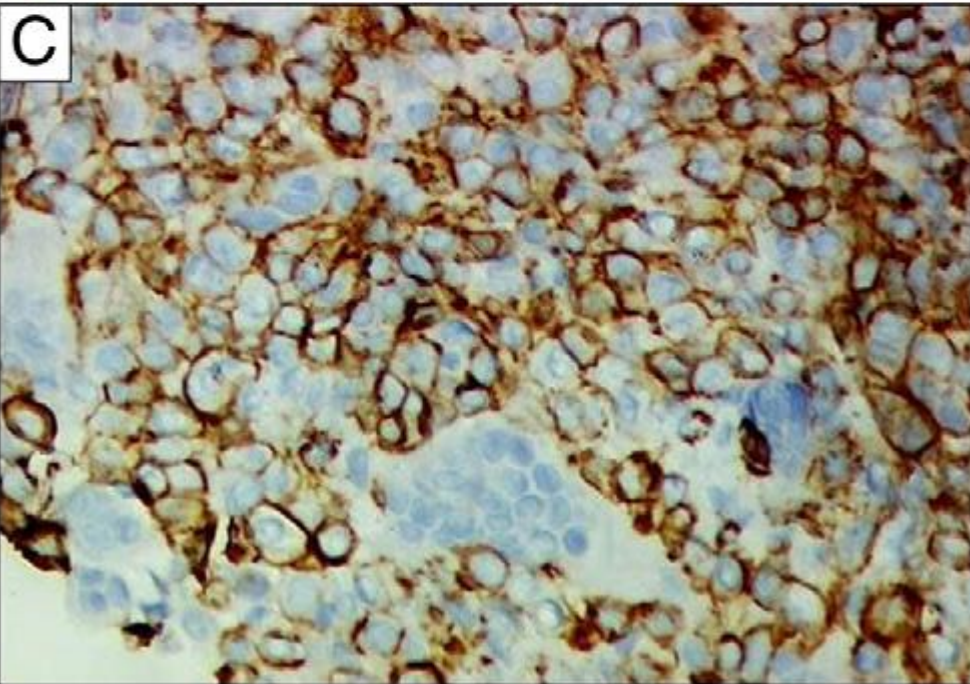
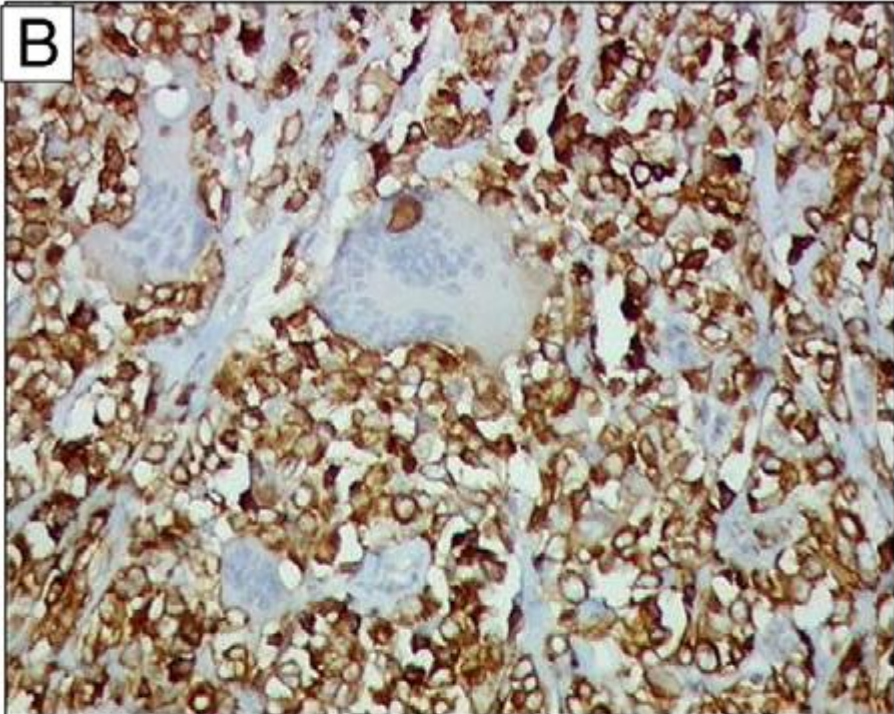
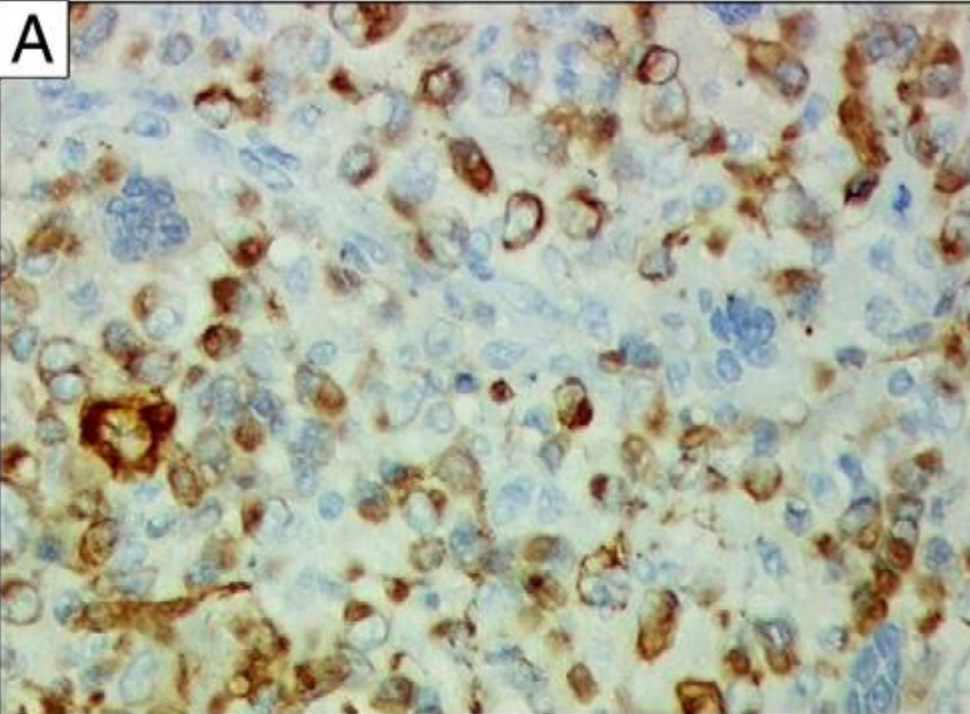
^b Department of Radiation Oncology, Tata Memorial Centre, Mumbai, Maharashtra, India

^c Department of Radiodiagnosis, Tata Memorial Centre, Mumbai, Maharashtra, India

^d Department of Surgical Oncology (Bone and Soft Tissues), Tata Memorial Centre, Mumbai, Maharashtra, India

ORPTES





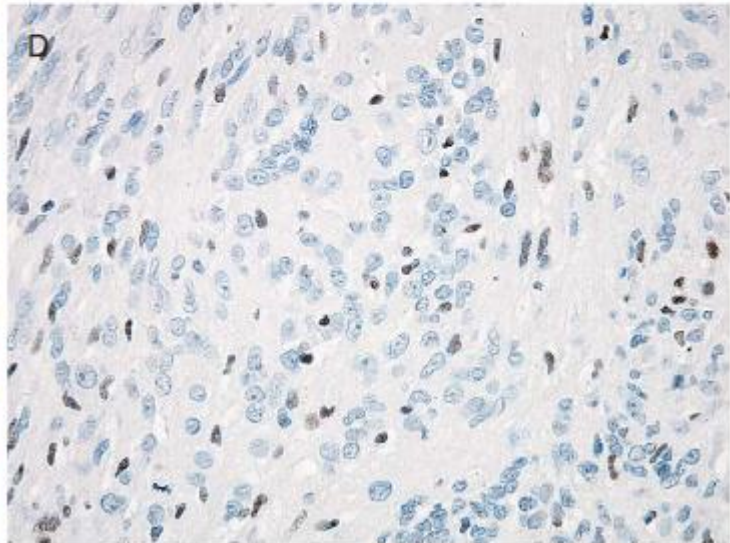
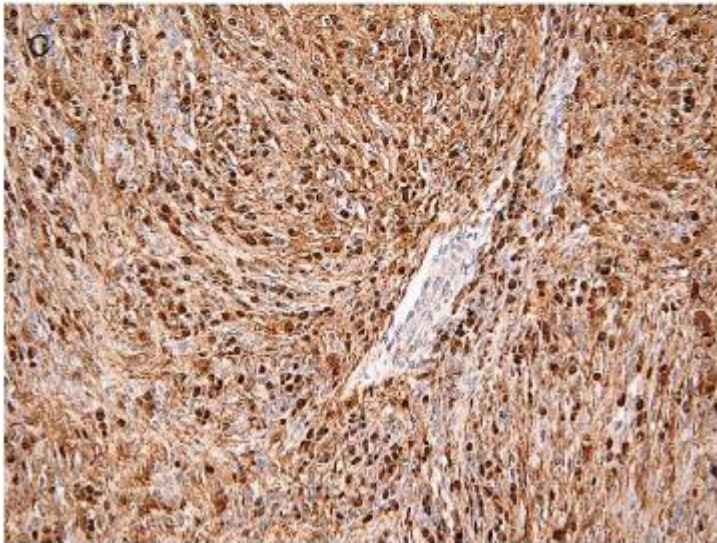
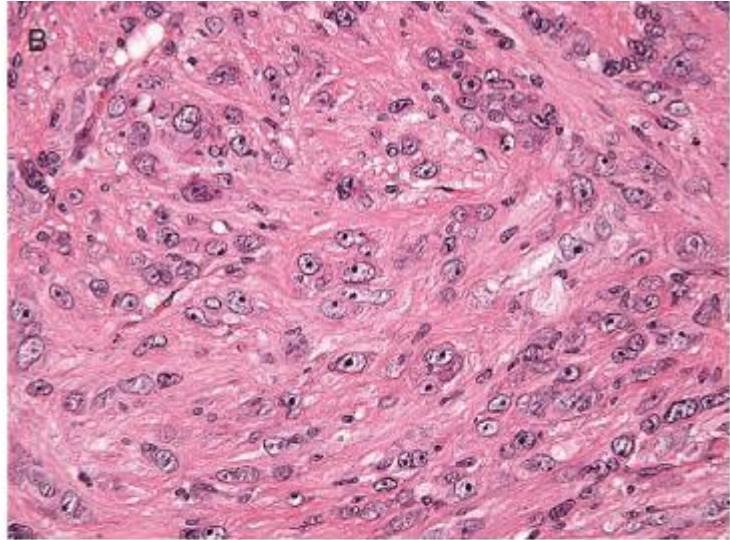
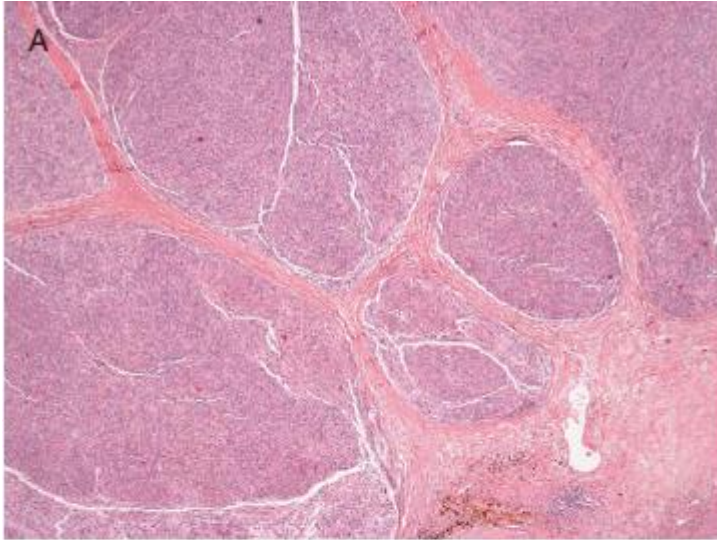
Dif. dg.

- Pigmentovaná vilonodulárna synovitída
- OBT mäkkých tkanív
- MFH („giant cell rich“)
- MTS nediferencovaný karcinóm bohatý na obrovské bunky podobné osteoklastom
- Extraskeletálny OSA
- RMS

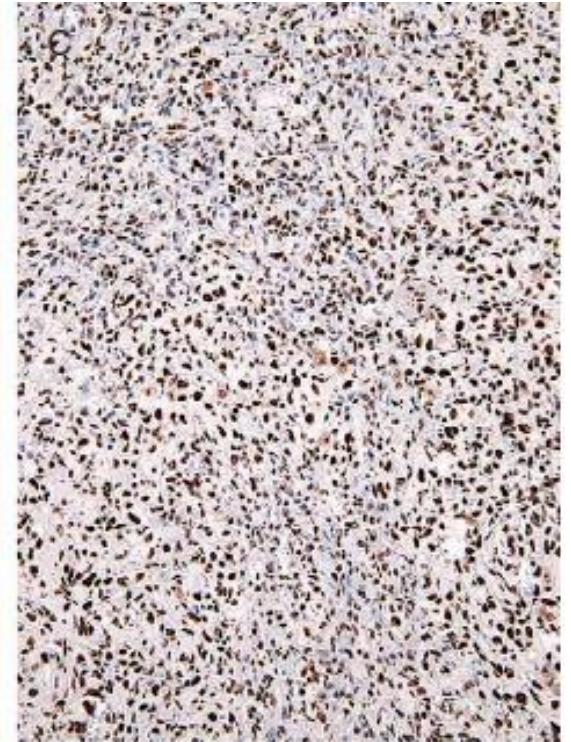
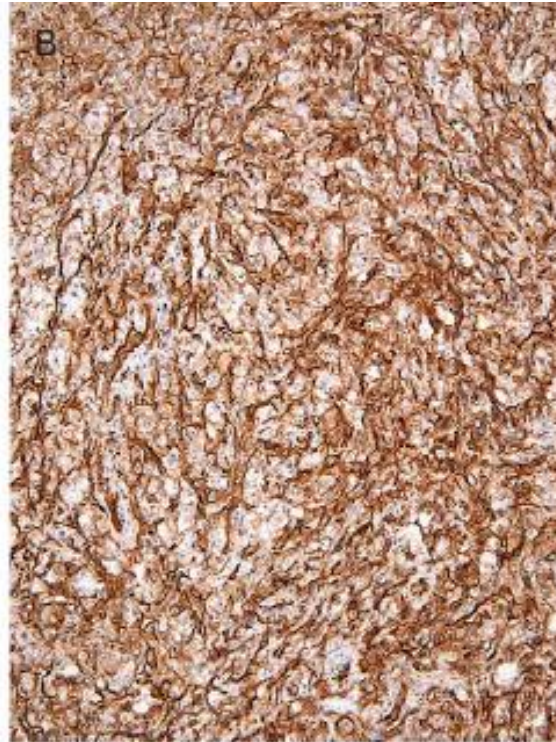
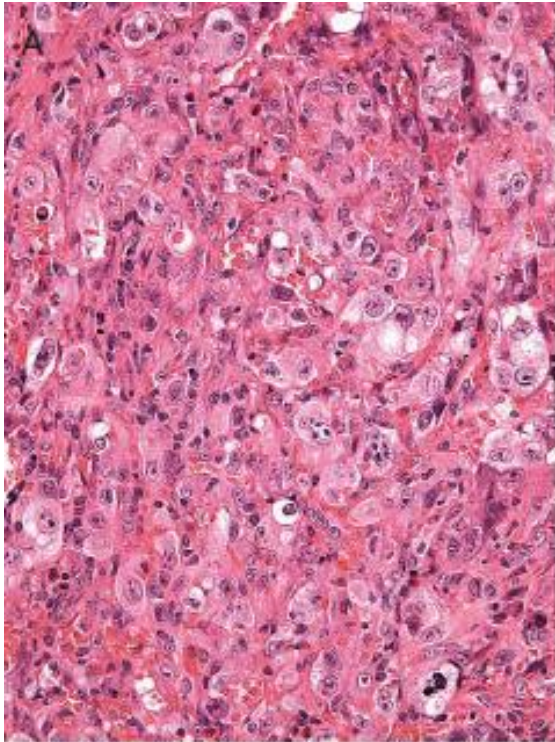
Dif. dg.

- ALCL
- Malígný mezotelióm
- Svetlobunkový sarkóm/malignant melanoma mäkkých častí
- Epithelioid AS
- Epithelioid MPNST.

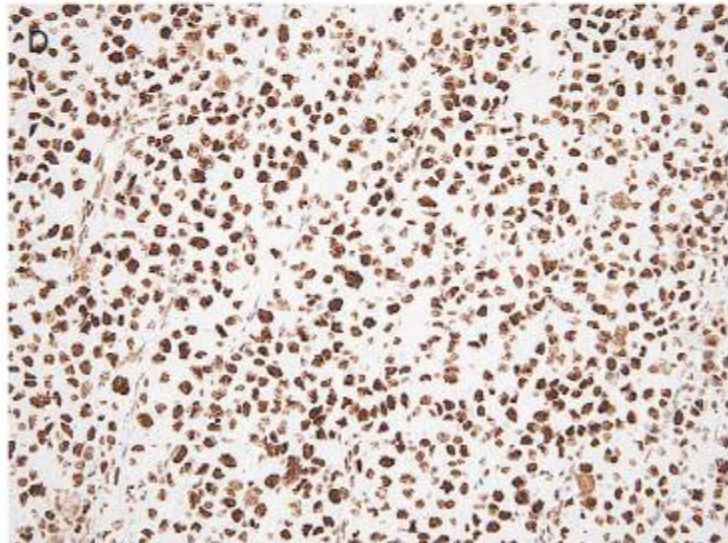
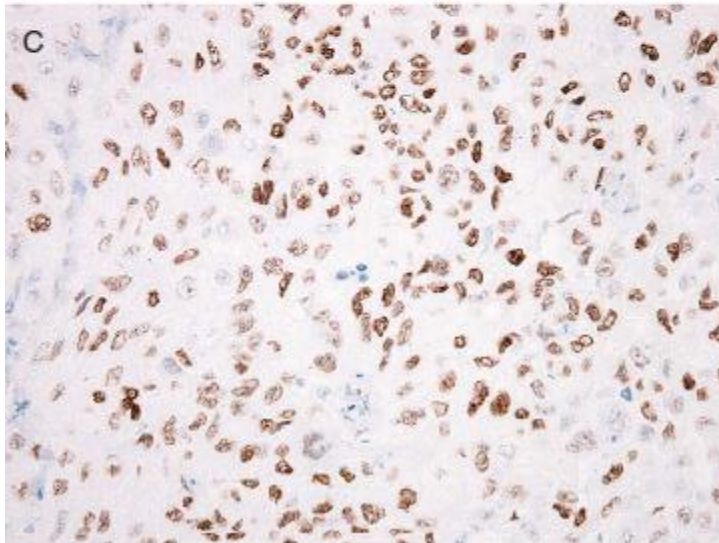
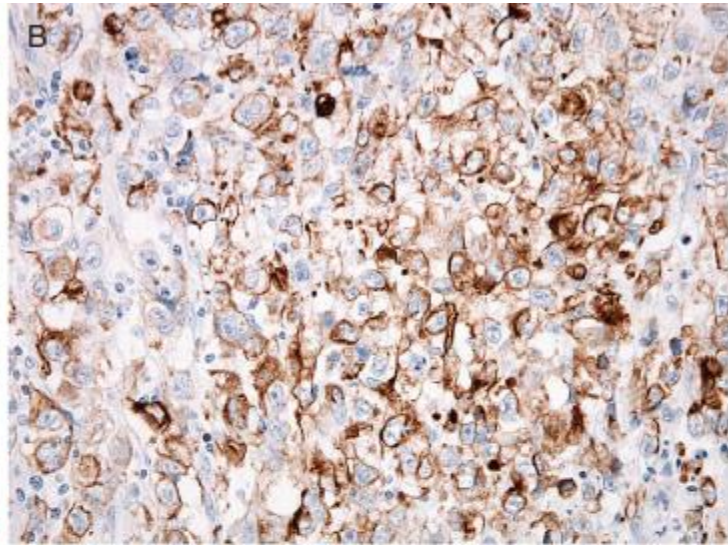
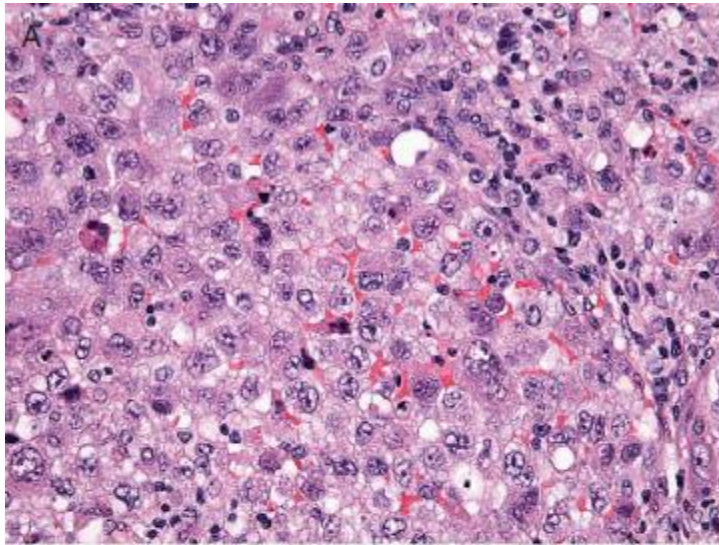
Epiteloidný MPNST



Epiteloidný ASA



MTS veľkobunkový ca



INI1 deficientné tumory

- Rhabdoidný tumor obličky
- Renálny medulárny karcinóm
- Epiteloidný MPNST
- Myoepiteliálny karcinóm
- EMCHSA

Záver

1. Variabilné histopatologické črty ES predstavujú často diagnostickú výzvu, hematoxylinová diagnóza nie je jednoduchá.
2. ORPTES je vzácny subtyp, môže imitovať iné nádory bohaté na obrovské bunky podobné osteoklastom
3. Kompletná strata INI1 bola pozorovaná v 50% až 100% prípadov of ES, bezohľadu na podtypy

Literatúra

- [1] Oda Y, Dal Cin P, Laskin WB. Epithelioid sarcoma. In: Fletcher CD, Bridge JA, Hogendoom PCW, Mertens F, editors. World Health Organization (WHO) classification of tumors of soft tissue and bone. 4th ed. Lyon, France: IARC Press; 2013. p. 216–8.
- [2] Guillou L, Wadden C, Coindre JM, Krausz T, Fletcher CD. “Proximal-type” epithelioid sarcoma, a distinctive aggressive neoplasm showing rhabdoid features. Clinicopathologic, immunohistochemical, and ultrastructural study of a series. *Am J Surg Pathol* 1997;21:130–46.
- [3] Miettinen M, Fanburg-Smith JC, Virolainen M, Shmookler BM, Fetsch JF. Epithelioid sarcoma: an immunohistochemical analysis of 12 classical and variant cases and a discussion of the differential diagnosis. *Hum Pathol* 1999;30:934–42.
- [4] Hasegawa T, Matsuno Y, Shimoda T, Umeda T, Yokoyama R, Hirohashi S. Proximal-type epithelioid sarcoma: a clinicopathologic study of 20 cases. *Mod Pathol* 2001; 14:655–63.
- [5] Rekhi B, Gorad BD, Chinoy RF. Clinicopathological features with outcomes of a series of conventional and proximal-type epithelioid sarcomas, diagnosed over a period of 10 years at a tertiary cancer hospital in India. *Virchows Arch* 2008;453: 141–53.
- [6] Modena P, Lualdi E, Facchini F, Galli L, Teixeira MR, Pilotti S, et al. SMARCB1/INI1 tumor suppressor gene is frequently inactivated in epithelioid sarcomas. *Cancer Res* 2005;65:4012–9.
- [7] Hornick JL, Dal Cin P, Fletcher CD. Loss of INI1 expression is characteristic of both conventional and proximal-type epithelioid sarcoma. *Am J Surg Pathol* 2009;33: 542–50.
- [8] Chbani L, Guillou L, Terrier P, Decouvelaere AV, Gregoire F, Terrier-Lacombe MJ, et al. Epithelioid sarcoma: a clinicopathologic and immunohistochemical analysis of 106 cases from the French sarcoma group. *Am J Clin Pathol* 2009;131:222–7.
- [9] Rekhi B, Jambhekar NA. Immunohistochemical validation of INI1/SMARCB1 in a spectrum of musculoskeletal tumors: an experience at a tertiary cancer referral centre. *Pathol Res Pract* 2013;209:758–66.
- [10] von Hochstetter AR, Grant JW, Meyer VE, Honegger HP, Schreiber A. Angiomatoid variant of epithelioid sarcoma. The value of immunohistochemistry in the differential diagnosis. *Chir Organi Mov* 1990;75:158–62.
- [11] Mirra JM, Kessler S, Bhuta S, Eckardt J. The fibroma-like variant of epithelioid sarcoma. A fibrohistiocytic/myoid cell lesion often confused with benign and malignant spindle cell tumors. *Cancer* 1992;69:1382–95.
- [12] Fadare O. Myxoid epithelioid sarcoma: clinicopathologic analysis of 2 cases. *Int J Surg Pathol* 2009;17:147–52.

